



# Clinical and morphological features of ovarian pure dysgerminoma: A report of a 14 years old girl

Zoran POP-TRAJKOVIĆ<sup>1</sup>  
Milena VELJKOVIĆ<sup>1</sup>  
Miodrag RADOVIĆ<sup>1</sup>  
Vuka KATIĆ<sup>2</sup>  
Aleksandar PETROVIĆ<sup>3</sup>  
Vekoslav LILIĆ<sup>1</sup>

<sup>1</sup>CLINIC OF OBSTETRICS AND GYNECOLOGY, MEDICAL FACULTY NIŠ, YUGOSLAVIA

<sup>2</sup>INSTITUTE OF PATHOLOGY, MEDICAL FACULTY NIŠ, YUGOSLAVIA

<sup>3</sup>INSTITUTE OF HISTOLOGY, MEDICAL FACULTY NIŠ, YUGOSLAVIA

*Dysgerminoma is best known as the ovarian counterpart of seminoma of the testis. Relatively uncommon tumors, dysgerminomas account for less than 2% of all ovarian cancer. We report a case of a 14 years old girl with a large and rapidly growing unilateral ovarian dysgerminoma. Examination of the surgical specimen showed a tumor of 27x17x8 cm in size and 4800 gr. in weight. It was oval in shape with a slightly glistening fibrous capsule, soft but solid and hemorrhagic. The mass arose from the right ovary and did not invade any surrounding structures. The tumor and the ovary were torqued with its fallopian tube. Microscopic examination showed typical characteristics of ovarian dysgerminoma, with a micrometastasis in the omentum (in the vicinity of the tumor). The patient underwent a right salpingo-oophorectomy, had an uncomplicated post-operative course and received radio- and chemotherapy. Thirty months after the operation, the patient is in good health and with normal ultrasound and laboratory results. We believe that conservative surgery followed by adjuvant radiotherapy and chemotherapy seems to be ideal treatment in case of pure ovarian dysgerminoma when careful surgical staging confirmed the unilaterality of disease.*

**KEY WORDS:** *Dysgerminoma; Adolescence*

*Archive of Oncology 2002, 10(4):281-282©2002, Institute of Oncology Sremska Kamenica, Yugoslavia*

## INTRODUCTION

**D**ysgerminoma is the ovarian counterpart of testicular seminoma and is composed of primordial germ cells (1,3,4). Although it accounts for less than 2% of all ovarian cancer (7) dysgerminoma is responsible for 10% for these cancers in woman younger than 20 years of age (5). Most patients are between 20 and 30 years of age. The tumors are bilateral in about 15% of cases (3,6). Some occur in patients with gonadal dysgenesis, including pseudo-hermaphroditism. Most of these tumors have no endocrine function. A few of them produce elevated levels of chorionic gonadotropin and may have syncytiotrophoblastic giant cells on histologic examination. All dysgerminomas are malignant, but the degree of histologic atypia is variable and only one third of them is aggressive.

## CASE REPORT

The patient, a 14 years old girl, complained of the 24-hour pain in

Address correspondence to:

Dr Zoran Pop-Trajković, Clinic of Obstetrics and Gynecology, Medical Faculty Niš, Yugoslavia

The manuscript was received: 23. 01. 2002.

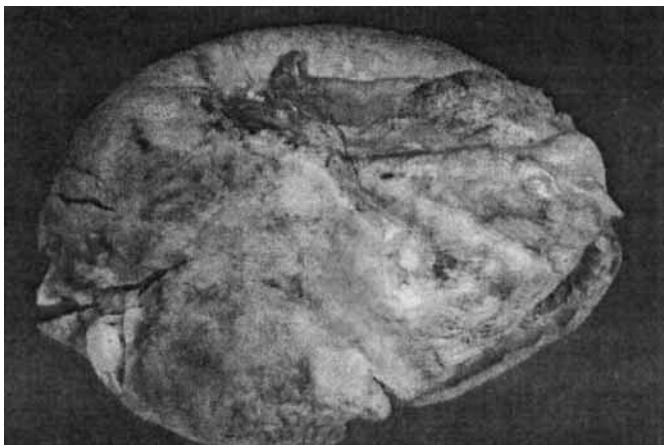
Provisionally accepted: 08. 03. 2002.

Accepted for publication: 25. 07. 2002.

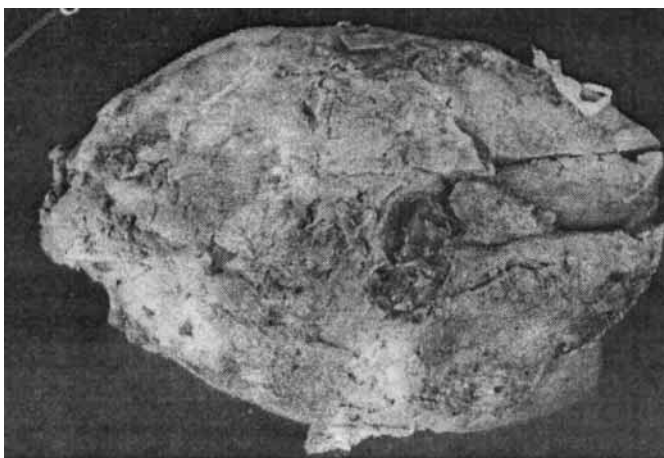
the right lower quadrant (suprapubic) and had a visible and palpable abdominal mass. During the last three days, girl's abdomen became so much gross that she looked like 7-month pregnant woman (anamnesic data). She had her first menstruation at 13 years of age. Palpable and visible abdominal mass of large size was found during clinical and physical examination. Except normochromic anemia other laboratory findings were noncontributory. The patient was operated on the first day of admission. The mass was observed to arise from right ovary. It was not macroscopically invading surrounding structures. The tumor and the ovary were torqued with its fallopian tube. The patient underwent a right salpingo-oophorectomy, partial omentectomy and a left partial oophorectomy.

Examination of the surgical specimen revealed the oval-shaped mass of 27 x 17 x 8 cm and 4800 gr. (Figure 1) with a tan colored outer surface. Extensive hemorrhage and necrosis were present. On cut surface, it was soft and flashy with a yellow-white appearance (Figure 2).

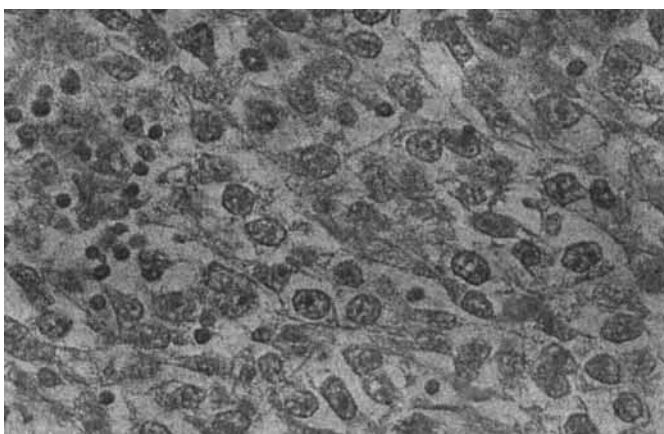
Microscopic examination showed typical characteristics for ovarian dysgerminoma. Neoplastic cells were dispersed in sheets and cords separated by scant fibrous stroma, as in seminoma, the fibrous stroma was infiltrated with mature lymphocytes (Figure 3.). The cytoplasm contained glycogen, thus the cells were PAS positive.



**Figure 1.** Dysgerminoma ovarii (27x17x7 cm, 4800 gr. of weight). Macroscopic aspect



**Figure 2.** Cut surface of dysgerminoma



**Figure 3.** Microscopic pattern HE x 300

Final diagnosis of our case was unilateral pure dysgerminoma that did not spread beyond the capsule. Only one micrometastasis was found microscopically in the omentum (stage III). The treatment consisted of simple salpingo-oophorectomy followed by adjuvant radiotherapy and chemotherapy. The patient had an uncomplicated post-operative course.

The follow-up of thirty months confirms that the patient is in good health condition and with normal ultrasound and laboratory results.

## DISCUSSION AND CONCLUSION

Dysgerminoma is the most common malignant ovarian germ cell tumor. It may occur at any age, but usually before age 30 (80% of cases). It is also one of the two most common ovarian neoplasms observed in pregnancy, the other being serous cystadenoma. Metastatic spread does not occur early in the course of disease, mostly via the lymphatic system and because of that a 5-year survival is 75-90% (2,3,7). One of the reasons for good prognosis is immunologic response to the tumor. Immunohistochemical investigations discovered marked cellular stromal reaction with formation of disseminated granulomas, similar to that seen in the closely related tumor, testicular seminoma (2,3). Mainly T cells (CD43+, CDRO+) and macrophages/epitheloid cells (MAC387+, CD68+) are found. In most cases of dysgerminoma B cells (CD20), natural killer cells (CD57+) and immune accessory cells (CD1+, CD35+) are rare. Virtually, no tumor cells have been found to express major histocompatibility complex (MHC) Class II antigens (2).

Unfavorable prognostic parameters include presence of metastases at the time of diagnosis, presence of adhesions and spread into adjacent structures, presence of bilateral tumor and presence of other neoplastic germ cell elements (6,8). Survival of patients with pure dysgerminoma was not affected by tumor size (3).

We believe that conservative surgery followed by adjuvant radiotherapy and chemotherapy seems to be ideal treatment in case of pure ovarian dysgerminoma when careful surgical staging confirmed the unilaterality of disease.

## REFERENCES

1. Ayhan A, Bildhlei I, Gunalp S, Yuce. Pure dysgerminoma of the ovary: a review of 45 well staged cases. *Eur J Gyneacol Oncol* 2000; 21(1): 98-101.
2. Dietl J, Horny HP, Ruck P, Kaiserling E. Dysgerminoma of the ovary, An immunohistochemical study of tumor-infiltrating lymphoreticular cells and tumor cells. *Cancer* 1993; 71(8): 2562-8.
3. Gordon A, Lipton D, Woodruff JD. Dysgerminoma a review of 158 cases from the Email Novak Gvarian tumor registry. *Obstet Gynecol* 1981; 58 (4): 497-504
4. Resta R, Sabatoni R, Restaino A. Ovarian dysgerminoma. A clinico-pathological study. *Neoplasma* 1984; 31(40):459-64.
5. Sunerwala SS, Pande SC, Shirvastava SK, Dinshaw KA. Dysgerminoma of the ovary: review of 27 cases. *J Surg Oncol*. 1991; 46(1):34-7.
6. Tewfik HH, Tewfik FA, Latourette HB. A clinical review of seventh patients with ovarian dysgerminoma. *Int J Radiat Biol Psych* 1982; 8(10):1705-9.
7. Young RH, Scully RE: Ovarian pathology in infertility. In Kraus FT (ed): *Pathology of Reproductive Failure*. Baltimore, Williams and Wilkins 1991;p.104-139.
8. Zhang R, Hong W, Li S. Dysgerminoma of the ovary: a clinical retrospective analysis of 60 cases. *Zhonghua Fu Chan Ke Za Zhi* 1995; 30(9):550-2.