

book review

Tibor Tot: Colorectal Tumors, Atlas of Large Section Histopathology **Thieme, Stuttgart, New York 2005**

The correct diagnosis and staging are essential in determining the appropriate therapy of colorectal carcinoma, one of the most common malignancies in Europe and America. In spite of rapid development that has taken place in many fields of modern medical science, histopathology remains essential in making or confirming diagnosis in malignant tumors of intestinal diseases. On the other hand, in the era of interdisciplinary medicine, the role of pathology has expanded to provide morphology images that easily correlate with endoscopic, radiological, or operative findings.

In this remarkable atlas, Tibor Tot (associated professor of pathology University of Uppsala School of Medicine, Head of Department of Pathology and Clinical Cytology, Central Hospital, Falun, Sweden), presents colon pathology in large histological sections, with cross-sections of entire tumors in their anatomic environments and their circumferential surgical margins. A large histological section is used traditionally in neuropathology, and in the author's department they are used routinely in operative breast specimens. This atlas is the result of seven years of studying almost 2,000 large histological sections of colorectal carcinoma and other intestinal lesions.

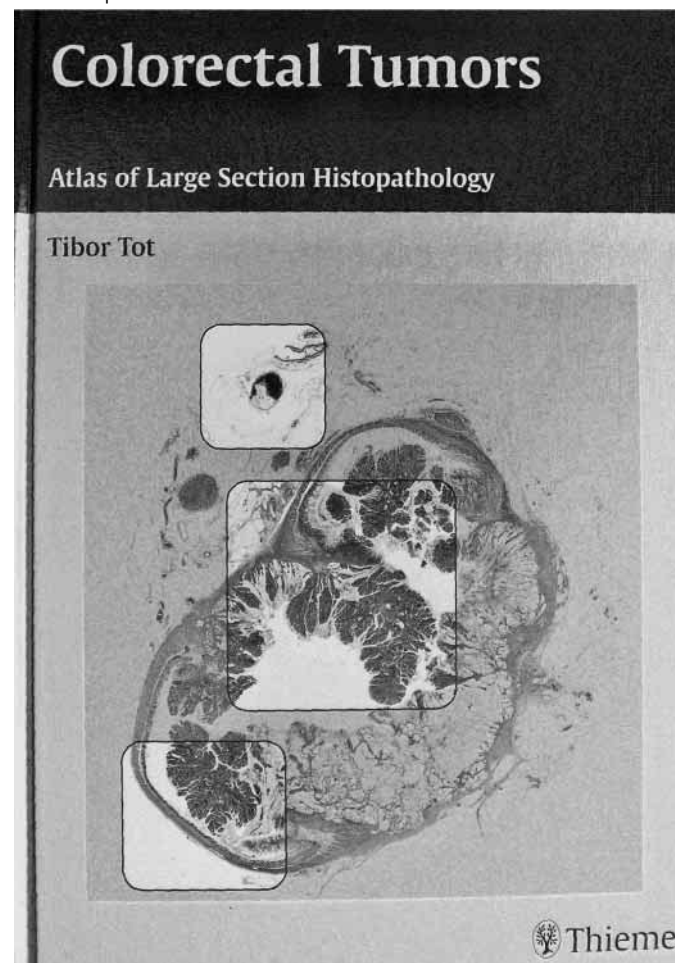
Large histologic sections, by preserving the contiguity of the tissue in representative transections of the bowel lesion, can bridge the gap between the endoscopic and the histologic appearance. Large histologic sections resemble the endoscopic findings and offer possibility to magnify the same section under microscope; they demonstrate the histologic and cellular details behind the subgross findings. Thus, this method can be an ideal approach to educating and training residents as well as specialists performing gastrointestinal endoscopy. Recent advances in modern radiology may revolutionize gastroenterology, such as virtual endoscopy that presents horizontal transections of the bowel wall. As this approach is identical to that offered by the histopathologic technique of large sections, this offers the possibility correlating and testing the accuracy of a new radiological method.

This technique, above all, offers advantage for pathologists to correct typing and staging of colorectal cancers and helps assessing the completeness of a surgical excision and understanding the heterogeneity of colorectal carcinomas. The proper staging of colorectal carcinomas is essential both for treatment and prognosis. Correct histopathology analysis helps the oncologists to design the postoperative treatment. Large histological sections, by showing the deepest level of invasion of the primary tumors together with the peritumoral tissue, which may contain isolated tumor foci and several lymph nodes, can help in proper tumor classification and staging.

Total mesorectal resection, removal of the tumor together with the mesorectal fat, has been introduced as a procedure of choice in rectal tumor surgery resulting decrease of the rate of local recurrence from 30-40% to less than 10%. Assessment of the radicality of surgical intervention has always been an important task of the pathologist. It has become increasingly important since 2 mm or more of free tissue in the circumferential margin may assure local control of the disease. By including the continuous circumferential margin in one

plane, the large histologic section is an ideal tool for assessing the radicality of mesorectal resection.

Transection of the entire tumor of the large histologic sections allows proper assessment of the proportions of different tumor types in cases of heterogeneous tumors, and assists in proper tumor typing. On the other hand, it makes possible the study of the pattern of invasive tumor growth. The inclusion of large area of the mesorectal/mesocolonic tissue of the large sections makes possible the analysis of pathologic details with prognostic relevance and included in TNM classification of colorectal tumors as a lymph nodes, isolated tumor foci in the mesocolon, vascular invasion, serosal involvement and continuous tumor spread in neighbourhood organs. Large histologic sections can easily be correlated with endoscopic and macroscopic findings and projection of images can successfully be used in clinicopathological conferences and in education of medical students or postgraduate education of different specialists.



The book contains 6 chapters on 152 pages with 293 illustrations. It presents the cases of adenomas, early colorectal cancer, advanced colorectal cancer, other intestinal neoplasms (gastrointestinal stromal tumor, intestinal lymphoma), and non-neoplastic lesions. The cases are illustrated in two-page spreads with clinical information, conventional histopathology, and large-section histology images enlarged to almost a full page. The last chapter contains detailed technical guidelines for obtaining large-section.

This book is highly recommended to pathologists, gastroenterologists, radiologists, surgeons, oncologists, and residents involved in the detection and therapy of colorectal cancer.

Attila Fenyvesi