



Staging of rectal cancer by endorectal ultrasonography

Zoran Radovanović, Milan Breberina, Tomislav Petrović, Andrija Golubović

ABSTRACT

Endorectal ultrasonography is valuable method for accurate local staging of rectal cancer. Precise evaluation of tumor stage is essential for optimal therapy planning in patients with rectal cancer. Furthermore, it has great influence on the resectability and the risk of recurrence following resection. Endorectal ultrasonography has become the most common diagnostic tool for locally staging rectal cancer due to its advantages over magnetic resonance imaging (MRI) and computer tomography (CT). Among these diagnostic modalities ERUS has been known to be most accurate. Moreover, endorectal ultrasonography is inexpensive and quick diagnostic procedure associated with minimal discomfort to the patient. However, the use of CT, MRI, and more recently magnetic resonance imaging with endorectal coil often remains necessary. These modalities may be useful supplements in patients with suspected T4 lesion, when endorectal ultrasonography is technically unsuccessful and in cases of diagnostic dilemma. Major improvements in diagnostic and staging of rectal cancer have led to stage-oriented surgery, planning of therapy individually for each patient, reduce of local recurrences, and better overall survival. This article reviews the current use of endorectal ultrasonography in preoperative staging of rectal cancer as the most practical and accurate diagnostic modality for preoperative locoregional staging of rectal cancer at this time.

Department of Surgical Oncology, Institute of Oncology Sremska Kamenica, Sremska Kamenica, Serbia; Address correspondence to: Dr. Zoran Radovanović, Department of Surgical Oncology, Institute of Oncology Sremska Kamenica, Instituitski put 4, 21204 Sremska Kamenica, Serbia, E-mail: zoran.r@eunet.yu; The manuscript was received: 20.01.2006, Provisionally accepted: 28.02.2006, Accepted for publication: 09.03.2006

©2006, Institute of Oncology Sremska Kamenica, Serbia

KEY WORDS: Rectal Neoplasms; Endosonography; Rectum; Neoplasm Staging; Preoperative Care

INTRODUCTION

The first step in the management of patients with newly diagnosed rectal cancer is to evaluate whether the disease is localized or whether there are any signs of distant spread. Secondly, local stage needs to be evaluated. Depending on the tumor stage different treatment concepts, including local excision, radical resection and multimodality therapy are available for patients with rectal cancer. Therefore, precise preoperative evaluation of tumor level and extent of tumor spread is essential for planning optimal therapy in these patients. Also, it has great influence on the resectability and the risk of recurrence following resection. Endorectal ultrasonography (ERUS) has added a new dimension to the evaluation of tumor invasion and lymph node involvement in rectal cancer. Several studies have shown that ERUS is practical, reliable and accurate diagnostic tool in rectal cancer staging and during the last decade it has become the most common diagnostic modality for locally staging rectal cancer. ERUS can be used to select patients with lesions that can be treated with local excision or sphincter-sparing surgery, often combined with radiation therapy, in situations otherwise requiring an abdominoperineal resection. ERUS can also be used to preoperatively identify patients with locally advanced or unresectable disease. Chemoradiation can then be given preoperatively, when it appears to be better tolerated and more effective than postoperative treatment (1). Unresectable tumors can often be downstaged sufficiently to allow their excision. In resectable disease, ERUS can also identify patients at high risk for recurrence who would benefit from adjuvant chemoradiation.

CLINICAL STAGE ASSESSMENT

Preoperative clinical staging of rectal carcinoma can be assessed using a variety of modalities: digital rectal examination (DRE), ERUS, computed tomography (CT) and magnetic resonance imaging (MRI).

DRE performed by an experienced surgeon has a reported accuracy of 40%-80% in predicting whether tumor is confined to the rectal wall or it has penetrated through the rectal wall into perirectal fat tissue and nearby surrounding pelvic structures (2-4). However, fine distinctions of depth of penetration are not possible. Assessment of lymph node involvement is very difficult, except in advanced stages. Also, in one-third of rectal cancers, the tumor is too proximal to be palpated. However, one should always perform DRE prior to other diagnostic procedures.

The value of CT in rectal cancer staging is limited mainly due to inability of CT to determine the depth of tumor invasion and its low sensitivity for malignant lymph nodes. The former is caused by the limited intrinsic soft-tissue contrast of CT that prohibits the visualization of the various layers of the bowel wall, and the latter because the detection of malignant lymph nodes is based on size (5). Accuracy rates reported for preoperative T stage ranges between 65%-75% and for N stage between 56%-66% (6,7). Nevertheless, CT can be used for treatment planning, detection of distant metastases and assessment of adjacent organ involvement.

MRI is often used for rectal cancer staging. Accuracy for tumor depth and nodal involvement

has been reported at 55%-89% and 60%-83% respectively in various studies (6-9). ERUS provides better accuracy rates for T and N stage but MRI shows clear images between rectal cancer and adjacent organs, lateral pelvic lymph node status, and possible levator ani invasion and therefore is irreplaceable in diagnostic evaluation of some cases. MRI with endorectal coil is new, promising technology with accuracy rates in rectal cancer staging similar to ERUS. However, its widespread use is still limited. ERUS is diagnostic procedure that has ability to differentiate rectal wall layers and identify perirectal lymph nodes. Due to its advantages over MRI and CT it has become the most common diagnostic tool for locally staging rectal cancer.

BASICS OF ERUS

Two fleet enemas are recommended few hours before examination. The patient is placed in the left lateral decubitus position. Prior to ERUS, the lesion is defined with careful DRE and rigid proctoscopy. Then the ultrasound probe is inserted gently above the tumor. Latex balloon that covers the probe is filled with degassed water or gel for better acoustic contact. Usually, 5, 7, 5, 10 and 12-MHz radial scanning transducers are used. These transducers usually provide transverse 360° scans in the longitudinal axis of the rectum. The higher frequency provides better visualization of layers of the rectal wall and perirectal lymph nodes while lower frequencies are used to evaluate deeper structures (11). The examination is complete when the entire tumor, rectum, mesorectum and surrounding structures are visualized thoroughly. Rectal wall layers are represented on ultrasonography as 5 alternating hyperechoic (white) and hypoechoic (black) lines (Figure 1). The innermost hyperechoic line is the interface between the balloon and the mucosa. The next line is the first hypoechoic line that represents mucosa and muscularis mucosae. The third line is the second hyperechoic line and represents the submucosa. Outer hypoechoic line is the fourth line and represents the muscularis propria. Outermost, the fifth line, is the hyperechoic line and represents the interface between muscularis propria and the perirectal fat (12).

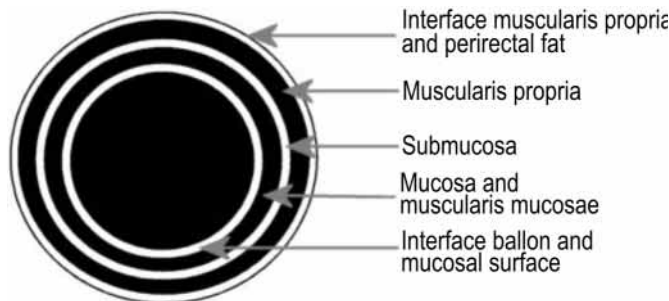


Figure 1. ERUS: layers of rectal wall (schema)

STAGING WITH ERUS

T stage

The endorectal sonographic staging of rectal cancer (uT) corresponds to the pathologic classification (pT) of the TNM system in which uT1 represents mucosal and submucosal disease, uT2 is disease involving the hypoechoic muscularis propria, uT3 is disease extension into the hyperechoic perirectal fat, and uT4 is disease into adjacent structures such as the bladder, prostate, seminal vesicles, vagina, cervix, pelvic sidewall or sacrum (Table 1). Transanal local resections with curative intent are limited to patients with uT1N0 rectal cancers. In cases of uT2 lesions radical resection is recommended (Figure 2). Conservative management may also be extended to patients identified with significant underlying comorbid conditions staged preoperatively as uT2 or uT3 lesions, often combined with adjuvant therapies in a palliative setting (12).

Table 1. Staging of rectal cancer by ERUS

uT0	Confined to mucosa (noninvasive lesion, thickening of the inner hypoechoic line)
uT1	Invasion of submucosa (middle hyperechoic line broken)
uT2	Invasion of muscularis propria (widening of the outer hypoechoic line but break in the outer hyperechoic line)
uT3	Invasion through bowel wall into perirectal fat (the outer hyperechoic line broken)
uT4	Involving adjacent structures
uN0	No definable lymph nodes by ultrasound
uN1	Ultrasonographically apparent lymph nodes

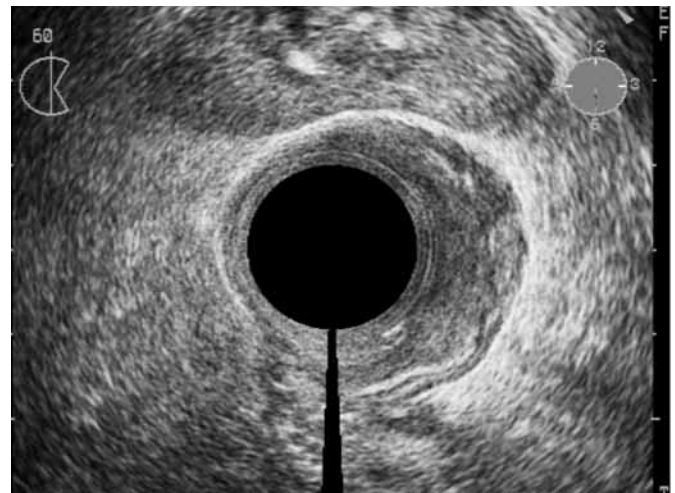

Figure 2. uT2 rectal cancer

If tumor is growing through the bowel wall (uT3 and uT4 lesions) multimodal treatment should be considered (Figure 3 and 4).

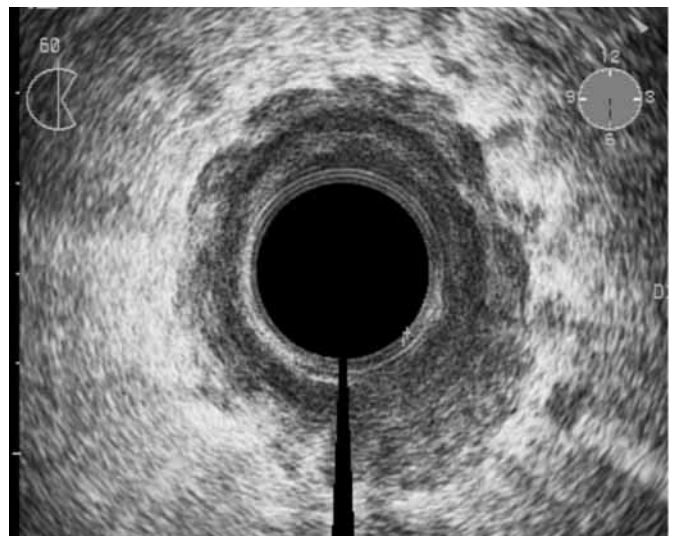

Figure 3. uT3 rectal cancer

A careful review of the literature reveals that accuracy of T staging with ERUS ranges from 67% to 94% (the majority reporting in the 80% to 90% range) (6,10,11,13-17). This is superior to both CT and MRI. Moreover, ERUS is inexpensive and quick diagnostic procedure associated with minimal discomfort to the patient. An addition benefit is that it is usually performed by the surgeon who can direct the examination with specific operative consideration in mind. However, the use of CT and MRI, if available, often remains necessary. These modalities may be useful supplements in patients with suspected T4 lesion, when ERUS is technically unsuccessful (in stenotic tumors ERUS is usually unfeasible) and in cases of diagnostic dilemma.

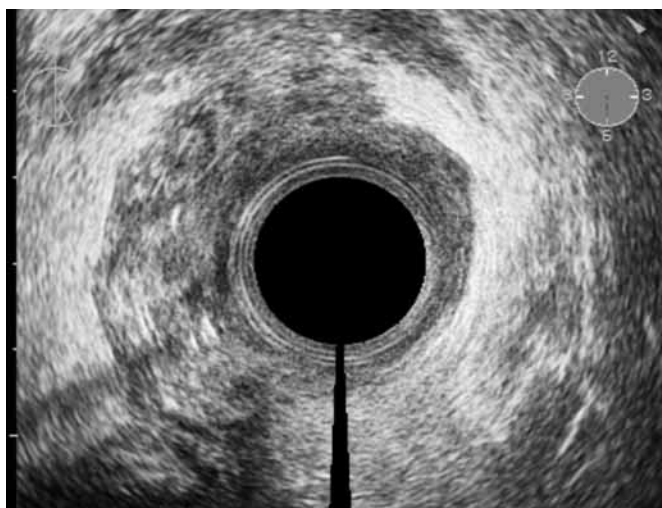

Figure 4. uT4 rectal cancer (invasion into posterior vaginal wall)

N stage

Normal, nonenlarged lymph nodes are similar in echogenicity to the hyperechoic perirectal tissues, and therefore are not usually seen. Enlarged inflammatory lymph nodes are also usually hyperechoic, with ill-defined margins. In contrast, malignant lymph nodes are usually located near the primary tumor site, round, with smooth, sharply defined margins, usually larger size (>5 mm) and echogenic characteristics similar to those of the primary tumor, which is usually hypoechoic (Figure 5). If no lymph nodes are seen, the designation uN0 is given or uN1 if enlarged, suspected nodes are noted. According to the literature, accuracy for detection of malignant lymph nodes ranges from 64% to 84% (Table 2).

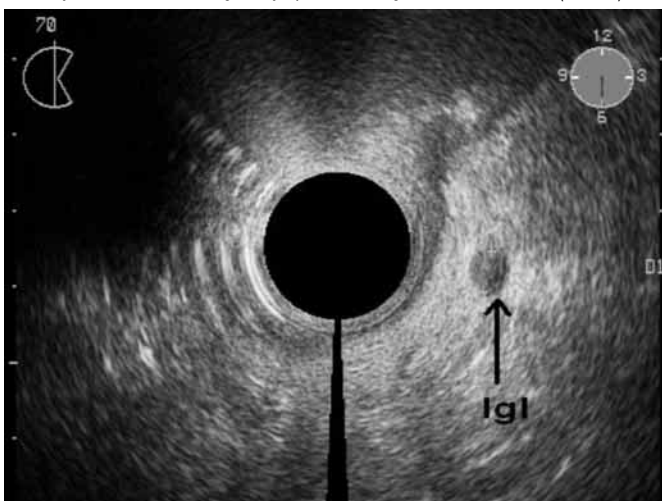

Figure 5. uN1 (metastatic lymph node in perirectal fat)

Table 2. Accuracy of ERUS in rectal cancer staging

Author	T stage (%)	N stage (%)
Beynon 1986.(20)	95	83
Goldman S. 1991. (21)	81	68
Herzog 1993. (22)	91	80
Starck M. 1995. (23)	88	71
Kim NK 1999.(7)	81	63
Garcia-Aguilar J 2002. (15)	69	64
Fuchsjager MH. 2003. (24)	64	70
Knaebel HP 2005. (25)	81	76

In general, ERUS is better at detecting lymph nodes in the distal and middle thirds of the rectum (13).

SOURCE OF ERRORS

T stage

Inflammatory and associated reactive changes in rectum wall and perirectal tissue, preoperative radiotherapy, postbiopsy changes and hemorrhage in the rectum wall are main causes of overstaging. They are presented as hypoechoic lesions and can be confused with carcinoma. A comparison of postirradiation ERUS with histopathology revealed that fibrosis became the morphologic basis of ultrasound images; therefore, after radiotherapy, what ERUS staged is no longer the tumor but the extent of fibrosis in the rectal wall. A histopathologic examination showed that the residual tumor, when present, was always within fibrosis, never outside or separate from it (18).

In stenotic cancers optimum positioning of the ultrasound probe can be difficult with possible understaging of the depth of tumor invasion. ERUS has limited examination field and therefore often fails in showing the tumor overgrowth in adjacent organs.

N stage

Although ERUS has allowed significant improvement in the accuracy of evaluation of N stage, diagnostic problems still exist.

The overstaging of lymph node status is primary caused by the presence of reactive swollen lymph nodes that could be considered as malignant. The small blood vessels, urethra, seminal vesicle and small bowel are known to be mistaken sometimes for metastatic lymph nodes (19). Even though blood vessels can simulate malignant nodes, they can be differentiated by moving the transducer to outline the linear course of the vessel.

Difficulty in detecting very small involved nodes (less than 3 mm) is main reason for understaging.

CONCLUSION

ERUS is currently the most practical and accurate diagnostic modality to preoperatively stage rectal cancer. Precise endosonographic preoperative assessment of T and N stages is crucial to determine the appropriate treatment strategy: local excision, radical resection, or radical resection preceded by neoadjuvant chemoradiation. Furthermore, ERUS may be of value in the postoperative management of patients treated conservatively for rectal cancers, and can lead to the early detection of local recurrence.

Note

All ERUS images in this article were obtained in Institute of Oncology Sremska Kamenica using Siemens Sonoline Sienna with Endo PII 7,5 MHz probe.

REFERENCES

- Pahlman L. Optimal staging and treatment of localised rectal cancer. *Ann Oncol* 2002;13:251-5.
- Nicholls RJ, Mason AY, Morson BC, Dixon AK, Fry IK. The clinical staging of rectal cancer. *Br J Surg* 1982;69:404-9.
- Stark M, Bohe M, Fork FT, Lindstrom C, Sjoberg S. Endoluminal ultrasound and low-field magnetic resonance imaging are superior to clinical examination in the preoperative staging of rectal cancer. *Eur J Surg* 1995;161:841-5.
- Beynon J, Mortensen N. Rectal endosonography in the preoperative staging and follow-up of rectal cancer. *Int Med* 1989;10:79-98.
- Pijl MEJ, Chaoui AS, Wahl RL, Van Oostayen JA. Radiology of colorectal cancer. *Eur J Cancer* 2002;38:887-98.
- Beynon J. An evaluation of the role of rectal endosonography in rectal cancer. *Ann R Coll Surg Eng* 1989;71:131-9.
- Kim NK, Kim MJ, Yun SH, Sohn SK, Min JS. Comparative Study of Transrectal Ultrasonography, Pelvic Computerized Tomography, and Magnetic Resonance Imaging in Preoperative Staging of Rectal Cancer. *Dis Colon Rectum* 1999;42(6):770-5.

8. Beets-Tan RGH, Beets GL, Vliegen RFA, Kessels AGH, van Boven H, De Bruine A, et al. Accuracy of magnetic resonance imaging in prediction of tumour-free resection margin in rectal cancer surgery. *Lancet* 2001;357:497-504.
9. Blomqvist L. Preoperative staging of colorectal cancer - computed tomography and magnetic resonance imaging. *Scand J Surg* 2003;92:35-43.
10. Maier AG, Kreuzer SH, Herbst F, Wrba F, Schima W, Funovics MA, et al. Transrectal sonography of anal sphincter infiltration in lower rectal carcinoma. *AJR* 2000;175:735-9.
11. Akbari RP, Wong WD. Endorectal ultrasound and the preoperative staging of rectal cancer. *Scand J Surg* 2003;92:25-33.
12. Beynon F, Foy DM, Temple LN, Channer JL, Virjee J, Mortensen NJ. The endoscopic appearances of normal colon and rectum. *Dis Colon Rectum* 1986;28:810-3.
13. Kim HJ, Wong WD. Role of Endorectal Ultrasound in the Conservative Management of Rectal Cancers. *Semin Surg Oncol* 2000;19:358-66.
14. Kwok H, Bisset IP, Hill GL. Preoperative staging of rectal cancer. *Int J Colorectal Dis* 2000;15:9-20.
15. Garcia-Aguilar J, Pollack J, Lee SH, de Anda EH, Mellgren A, Wong WD, et al. Accuracy of Endorectal Ultrasonography in Preoperative Staging of Rectal Tumors. *Dis Colon Rectum* 2002;45:10-5.
16. Nesbakken A, Lovig T, Lunde OC, Nygaard K. Staging of rectal carcinoma with transrectal ultrasonography. *Scand J Surg* 2003;92:125-9.
17. Akasu T, Kondo H, Moriya Y, Sugihara K, Gotoda T, Fujita S, et al. Endorectal ultrasonography and treatment of early stage rectal cancer. *World J Surg* 2000;24(9):1061-8.
18. Gavioli M, Bagni A, Piccagli I, Fundaro S, Natalini G. Usefulness of endorectal ultrasound after preoperative radiotherapy in rectal cancer: comparison between sonographic and histopathologic changes. *Dis Colon Rectum* 2000;43(8):1075-83.
19. Kruskal JB, Kane RA, Sentovitch SM, Longmaid HE. Pitfalls and sources of error in staging rectal cancer with endorectal US. *Radiographics* 1997;17:606-26.
20. Beynon J, Mortensen NJ, Foy DM. Preoperative assessment of local invasion in rectal cancer: digital examination, endoluminal sonography or computed tomography? *Br J Surg* 1986;73:1015-7.
21. Goldman S, Arvidsson H, Norving U, Lagerstad T, Magnusson I, Frisell J. Transrectal ultrasound and computed tomography in preoperative staging of lower rectal adenocarcinoma. *Gastrointestinal Radiol* 1991;16:259-63.
22. Herzog U, von Flue M, Tondelli P, Schuppisser JP. How accurate is endorectal ultrasound in the preoperative staging of rectal cancer? *Dis Colon Rectum* 1993;36:127-34.
23. Stark M, Bohe M, Fork FT, Lindstrom C, Sjoberg S. Endoluminal ultrasound and low-field magnetic resonance imaging are superior to clinical examination in the preoperative staging of rectal cancer. *Eur J Surg* 1995;161:841-5.
24. Fuchsjaeger MH, Maier AG, Schima W, Zebelin E, Herbst F, Mittlböck M, et al. Comparison of Transrectal Sonography and Double-Contrast MR Imaging When Staging Rectal Cancer. *AJR* 2003;181:421-7.
25. Knaebel HP, Koch M, Feise T, Benner A, Kienle P. Diagnostics of rectal cancer: endorectal ultrasound. *Recent Results Cancer Res* 2005;165:46-57.