



Borderline ovarian tumors

Katarina Mastilović, Tatjana Ivković-Kapicl, Milica Živaljević, Jelka Rajović,
Dejan Ninčić

ABSTRACT

Institute of Oncology Sremska Kamenica, Sremska Kamenica, Serbia; Address correspondence to: Dr. Katarina Mastilović, Institute of Oncology Sremska Kamenica, Institutski put 4, 21204 Sremska Kamenica, Serbia; The manuscript was received: 02.02.2006, Provisionally accepted: 10.04.2006, Accepted for publication: 14.04.2006

© 2006, Institute of Oncology Sremska Kamenica, Serbia

*Borderline ovarian tumors are classified between benign cystadenoma and malignant cystadenocarcinoma. They are characterized as malignant tumors by histopathological features, which make them different from the benign ones. These tumors are commonly diagnosed at the early disease stage. The treatment of these tumors is surgical. The prognosis depends on the stage of disease and histopathological types. We present 10 patients operated at the Institute of Oncology Sremska Kamenica because of malignant tumors with low malignant oncogenic potential in the period between 2000 and 2005. All patients had surgical treatment with *ex tempore* diagnostics, hysterectomy and adnexectomy with total omentectomy, or unilaterals adnexectomy. All patients had negative cytoanalytic findings of the small pelvis. Histopathological findings are necessary to confirm the diagnosis of disease. In young patients who had no children fertility can be preserved.*

KEY WORDS: Ovarian Neoplasms; Non MeSH Borderline Neoplasms

INTRODUCTION

According to the ovarian tumor classification, borderline ovarian tumors are classified between benign cystadenoma and malignant cystadenocarcinoma. These tumors were first described in 1929 by Taylor and they are characterized by special histopathological features that make them different from the benign ones. These tumors are malignant by their origin but their biological behavior is different from solely malignant forms. The course of a disease is slower which makes the prognosis of the disease better for a patient. That is why they are called the tumors of the low malignancy level or the tumors of the low malignant potential. These tumors were recognized by the FIGO as a separate entity in 1961 and introduced in the World Health Organization nomenclature in 1973. They occur in two forms: as serous and as mucinous border line tumors by epithelial origin. The serous borderline tumors occur much more often than the mucinous ones while the endometrial ones, clear cell and Brenner type, are very rare. Borderline ovarian tumors are not described along with non-epithelial tumors (1). There are not many information on the risk factors of these tumors. It is well known that women with infertility and those who have never given a birth are more likely to become ill. Breast-feeding and previous pregnancies decrease the risk of these tumors. The effect of birth-control pills is still controversial (1,2).

These tumors make 1%-2% of all malignant ovarian tumors. The majority of solely malignant are diagnosed in progressive or even terminal disease stage when metastases appear, while these tumors are mostly diagnosed in the first stage. The metastases very rarely appear with these tumors as well as the relapse of the disease and they occur approximately in 15%-20% of the cases. The serous borderline tumors give metastases more often than the mucinous one (3).

Although rare, the metastases of these tumors can usually be found on the peritoneum of the small pelvis and the abdomen, while farther metastases have been described very

rarely. The relapse usually occurs after a long time and the latent period can last up to two or even three decades. Due to the timely disease diagnosis and the rare occurrence of metastases, the prognosis is very good (4,5). Borderline tumors are usually unilateral while bilateral occurrence is very rare. For that reason, the lower stage is more common.

The tumors of the lower malignant potentials occur with younger women, between 20 and 40 years old, but they can also occur with older women, and after the menopause.

Considering the low malignancy of these tumors, the patients' fertility can be preserved by conservative surgical treatment. The stages of borderline ovarian tumors are determined in the same way as with other malignant ovarian tumors and according to the FIGO classification, they are divided into 4 stages of the disease (6,7). The clinical picture of these tumors is usually dominated by unilateral tumor mass, which can be large and accompanied with compressive symptomatology, pain, stomach swell, irregular vaginal hemorrhage or the disease can be asymptomatic. The diagnosis of these tumors along with the clinical examination, US findings and NMR is not specific. The definite diagnosis is made by histopathological confirmation taking into consideration certain parameters: excessive cell stratification, the existence of nuclear atypia, mitotic activity and without the ovarian stroma invasion (8). The treatment of these tumors is solely surgical. According to the treatment protocol at more progressive stages of the disease, a hysterectomy must be done with the adnexectomy on both sides and the total omentectomy (9).

At the first stage of the disease, a conservative surgical treatment can be done in order to preserve fertility. The treatment includes the removal of the ill ovary with *ex tempore* diagnostics and the biopsy of the other ovary and the omentum. For the purpose of the correct staging, the cytoanalysis of the small pelvis or ascites if present. The attitudes toward the use of chemotherapy still vary, but progressive disease or a large tumor mass is the indication for further treatment.

The prognosis for these tumors depends on the stage of the disease and the histological type. The risk of metastases and disease relapse is smaller with patients younger than 40 especially if they are in the first disease stage of the mucinous tumor. The patients with high risk are those who are over 70 with the serous type and the third disease stage (10).

CASE REPORT

The work describes 10 patients operated at the Institute of Oncology Sremska Kamenica because of the malignant tumors of the low oncogenic potential in the period between 2000 and 2005. Before the operation and after the clinical examination all patients went through additional diagnostics: US of the small pelvis and the upper abdomen, the serum level of tumor marker Ca125, X-ray of the chest and laboratory analysis.

The average age of the operated patients is 50. The youngest patient was 38 and the oldest one was 67. Five of them were in the postmenopausal age. Five patients had the borderline tumors on both ovaries while the other five had unilaterally localized tumors. All the patients had normal US findings of the upper abdomen as well as normal X-ray of the chest and other pre-operative laboratory findings. The level of the associated tumor antigen Ca125 showed increased values but not over 60.

Five patients had hysterectomy with adnexectomy on both sides and total omentectomy. Three patients had hysterectomy with adnexectomy. One patient had hysterectomy with unilateral adnexectomy while the other one had unilateral adnexectomy with the biopsy of the other ovary. *Ex tempore* diagnostics was done intraoperatively with all operated patients and that determined the further course of the treatment. All of them had the negative cytanalytic findings of the small pelvis. In all patients, histopathological finding was serous borderline ovarian carcinoma. In all cases staging of disease was I a (Figure 1). Due to the large tumor mass, four patients were postoperatively given the chemotherapy according to the carboplatin and Endoxan protocol in specific doses during three series.

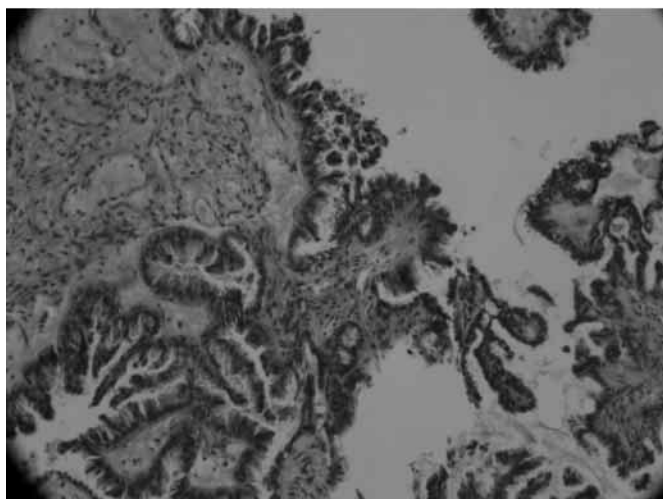


Figure 1. Borderline tumor of the ovary - histopathological finding

DISCUSSION

Borderline ovarian tumors are very rare primary ovarian tumors, which can occur with women of different age. These tumors are mostly found at the early disease stage and they very rarely give metastases. The choice of operative treatment depends on the disease stage and patient's age. The third condition can be patient's wish to preserve her fertility. In our case, with all postmenopausal women and with those who had borderline ovarian tumors on both sides we did hysterectomy with adnexectomy and total omentectomy (11). The patients with unilateral tumors had hysterectomy with adnexectomy on both sides while one patient who had not had children had adnexectomy with the biopsy of the other ovary

with the purpose of fertility preservation (12).

The clinical examination of a patient within pre-operative treatment and additional diagnostics - US of the small pelvis, CT of the abdomen and NMR, are not sufficient to create the complete picture of the disease. Histopathological findings are necessary to confirm the diagnostics. The optimal monitoring of these patients is based on the regular check-ups. Transvaginal US examinations are much more important than the determination of tumor associated gene Ca125.

REFERENCES

1. Poncelet C, Fauvet R, Boccarda J, Darai E. Recurrence after cystectomy for borderline ovarian tumors: Results of a French multicenter study. 14th International Meeting of the European Society of Gynecological Oncology; 2005 September 25-29; Istanbul, Turkey (abstr.). *Int J Gynecol Cancer* 2005;15:51.
2. Burger CW, Prinszen HM, Baak JP, Wagenaar N, Kenemans P. The management of borderline epithelial tumors of the ovary. *Int J Gynecol Cancer* 2000;10(3):181-97.
3. Camatte S, Morice P, Thoury A, Fourchotte V, Pautier P, Lhomme C, et al. Impact of surgical staging in patients with macroscopic "stage I" ovarian borderline tumors: analysis of a continuous series of 101 cases. *Eur J Cancer* 2004;40:1842-9.
4. Colgan TJ, Norris HJ. Ovarian epithelial tumors of low malignant potential: A review. *Int J Gynecol Pathol* 1983;1:367-82.
5. Marcickiewicz J, Brannstorm M. Results of conservative management of borderline ovarian tumors. 14th International Meeting of the European Society of Gynecological Oncology; 2005 September 25-29; Istanbul, Turkey (abstr.). *Int J Gynecol Cancer* 2005;15:69.
6. Fauvet R, Poncelet C, Boccarda R, Descamps P, Fondrinier E, Darai E. Fertility after conservative treatment for borderline ovarian tumors: A French multicenter study. *Fertil Steril* 2005;83(2):284-90.
7. Trope C, Kaern J. Management of borderline tumors of the ovary: state of the art. *Semin Oncol* 1998;25:372-80.
8. Seidman JD, Kurman RJ. Subclassification of serous borderline tumors of the ovary into benign and malignant types. A clinicopathologic study of 65 advanced stage cases. *Am J Surg Pathol* 1996;20:1331-45.
9. Trimble CL, Kosary C, Trimble EL. Long-term survival and patterns of care in women with ovarian tumors of low malignant potential. *Gynecol Oncol* 2002;86:34-7.
10. Ahmed ASM, Lawton FG. Borderline ovarian tumors: Current concepts and management. *Rev Gynaecol Practice* 2005;5(3):139-51.
11. Zanetta G, Rota S, Chiari S, Bonazzi G, Bratina G, Mangioni C. Behavior of borderline tumors with particular interest to persistence, recurrence and progression to invasive carcinoma: a prospective study. *J Clin Oncol* 2001;19:2658-64.
12. Crispens MA, Bodurka D, Deavers M, Lu K, Silva EG, Gershenson DM. Response and survival in patients with progressive or recurrent serous ovarian tumors of low malignant potential. *Obstet Gynecol* 2002;99:33-10.