

Testicular fibroma: a case report

Sunita K. Shere, Anjali S. Kulkarni, Shubhjyoti Pore, Rajan S. Bindu

SUMMARY

Testicular fibroma of gonadal stromal origin is a rare benign tumor of testis, which usually presents as a slow growing testicular mass. Intratesticular fibroma of gonadal stromal origin, with or without minor sex cord elements, must be considered, analogous to similar tumors in ovary, as a benign tumor. Until now, only 25 cases of testicular fibroma have been reported in the literature. We reported a case of testicular fibroma in a 20 years male who presented with painless right testicular enlargement since two years. Ultrasonography (USG) showed heterogeneous mass in right scrotum suggestive of testicular malignancy. Right orchidectomy was done. Histopathological diagnosis was testicular fibroma, which was confirmed by immunohistochemistry.

Key words: Testicular Neoplasms; Fibroma; Immunohistochemistry

INTRODUCTION

Testicular fibroma (TF) is a rare benign tumor, which, according to the WHO, belongs to the fibroma-thecoma group (1). Fibromatous tumors of the testis are rare neoplasms. They include paratesticular lesions (fibromas of testicular tunica and myofibroblastic pseudotumor) and the even more uncommon fibrous intratesticular lesions, which has been designated as under many different names. These lesions have been reported as testicular fibroma, unclassified sex cord stromal tumor, benign gonadal stromal tumor of spindle fibroblastic type, testicular stromal tumor with myofilaments, myoid gonadal stromal tumor with epithelial differentiation, and recently as fibroma of gonadal stromal origin (2). Literature recorded only 25 cases (3). It occurs predominantly in the third and fourth decade of life. The tumor grows slowly, sometimes accompanied by pain (3). Hormone disorders, metastasis or disease relapse are not reported (4).

CASE REPORT

A 20-years man presented with painless right testicular enlargement since two years. USG showed heterogeneous mass in right scrotum suggestive of testicular malignancy. Right orchidectomy was done and specimen sent for histopathology. On gross examination, we received a mass of 16 x 10 x 7 cm, which was circumscribed, firm, and whitish. Necrosis and hemorrhage was not seen.

The light microscopy showed a capsule underneath the tumor tissue that consisted of spindle shaped cells arranged in bundles and fascicles separated by hyalinized fibrocollagenous stroma containing scattered blood vessels. The spindle cells are arranged, in some areas, in a storiform pattern. They have scant, slightly eosinophilic cytoplasm and elongated nuclei with tapered ends. Neither normal testicular tissue seen nor sex cord component were seen. Mitosis, necrosis, and hemorrhage were not present. Based on histopathology findings the patient was diagnosed with testicular fibroma.

On immunohistochemistry analysis, spindle cells were focally positive for vimentin and desmin, negative for cytokeratin, S100 protein, and CD99, which confirmed the diagnosis of testicular fibroma.

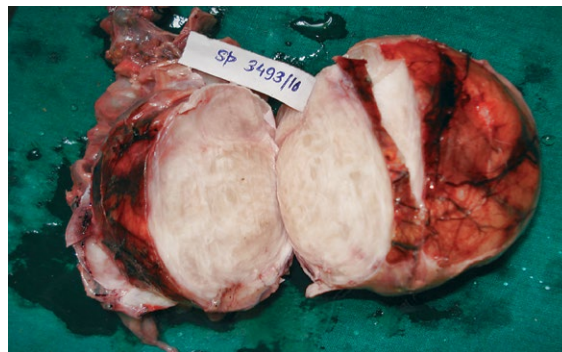


Figure 1. Testicular mass of size 16x10x7 cm, well circumscribed, firm, whitish.

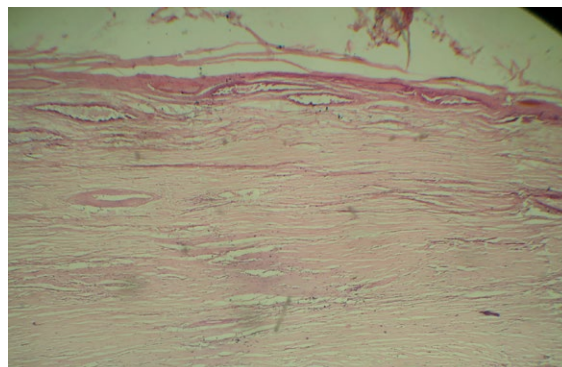


Figure 2. Section showing bundles of bland spindle shaped cells separated by fibrocollagenous stroma Haematoxylin and Eosin, 40x

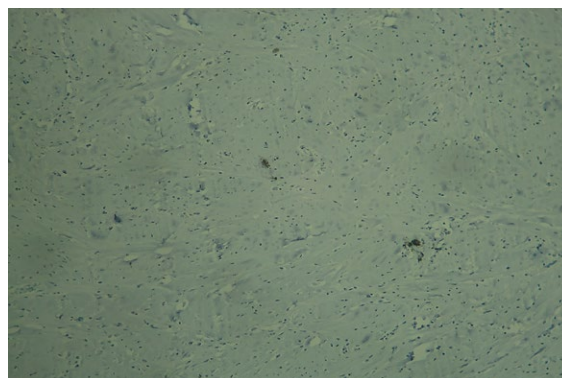


Figure 3. Immunohistochemistry showing focal positivity for Vimentin.40x

Arch Oncol 2013;21(3-4):139-40.

UDC: 616.681-006.03:577.27

DOI: <https://doi.org/10.2298/AO01304139S>

Department of Pathology, Government Medical College, Aurangabad, India

Correspondence to:
Dr. Sunita K. Shere [Harbade],
Plot no.18 vasundhara colony,
Nandanvan bhavsinghpura road,
Aurangabad, India

aharbade@yahoo.com

Received:03.12.2013

Provisionally accepted: 06.12.2013

Accepted: 11.12.2013

© 2013, Oncology Institute
of Vojvodina, Sremska Kamenica

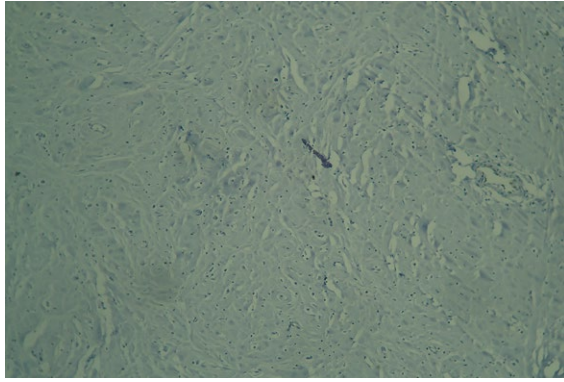


Figure 4. Immunohistochemistry showing negativity for S -100.40x

DISCUSSION

According to the recent WHO classification, testicular fibromas (TF) of gonadal stromal origin are classified under the sex cord/gonadal stromal tumor (1). These tumors constitute 4% to 6% of all testicular tumors in adult males. The youngest patient diagnosed with the TF was only 2 years and the oldest was 67 (3). The average age of patients with TF is 31 years (3). Only in small number of cases, TF grows rapidly and it is accompanied by pain (3, 4). In our case, the patient denied any infection or trauma in the area of the testicle, which is consistent with the data from Deveci et al. (5). These tumors are firm, well-circumscribed, encapsulated nodules, measuring 0.8-7 cm in diameter. They are yellow-white to white in color, without hemorrhage or necrosis (4). Microscopically, it is composed of spindle cells arranged in a swirling or fascicle formation. These cells are separated by fibrocollagenous, partly hyalinized stroma with many capillaries. Mitosis are rare, 1 to 2 per 10 high power field (HPF), although, even 4 mitosis per 10 HPF are tolerated (3). Calcifications in this tumor are rare, but Deveci et al. described a case of TF with numerous calcifications (5). Immunohistochemical expression for vimentin, actin, desmin, S-100 protein, CD 4, cytokeratin (CK), and MIC 2 is present in most tumor cells (8-10). The differential diagnosis includes leiomyoma, neurofibroma, solitary fibrous tumor, and fibrosarcoma. When it comes to setting a definite diagnosis, the application of immunohistochemical methods plays an important role. TF and leiomyoma are positive for vimentin, desmin, and smooth muscle actin. Aiding the differential diagnosis of these two tumors is the sex cord finding and a positive reaction to MIC2 and inhibin in the TF. Neurofibromas are positive for S-100 protein, but negative for actin, desmin, MIC2, and anti-inhibin. Fibro sarcoma is made up of tumor cells with prominent atypia, along with numerous mitotic figures (3, 4). Jones and Miettinen monitored TF patients. There were no records of recurrences or metastases of the tumor in their patients (6). Given that, the testicular fibroma may or may not contain elements of sex cords, and bearing in mind that the testicular stroma is of the same origin as ovarian stroma (2). TF is a counterpart to ovarian fibroma, according to its histomorphological and immunohistochemical features (3, 4). In our patient, as well as with Deveci, no elements of sex cords were registered, thus it was possible to set the differential diagnosis via standard H&E staining method (5). On follow-up, our patient did not show any signs of recurrence or metastasis until three years. Therefore, the choice of treatment is orchidectomy (3- 5).

CONCLUSION

Knowledge of this uncommon entity is important because it is one of the rare benign intratesticular tumors that can be successfully treated.

Conflict of interest

We declare no conflicts of interest.

REFERENCES

- 1 World Health Organization Classification of Tumours. IARC. Tumours of the testis and paratesticular tissue. Lyon; 2004. p. 257.
- 2 Pinieux G, Glaser C, Chatelain D, Perie G, Flam T, Vieillefond A. Testicular fibroma of gonadal stromal origin with minor sex cord elements - clinicopathologic and immunohistochemical study of 2 cases. *Arch Pathol Lab Med.* 1999;123:391-4.
- 3 Tegeltija D, Lovrenski A, Panjković M, Eri Ž, Klem I. Testicular (gonadal stromal) fibroma: case report. *Arch Oncol.* 2012;20(1-2):26-7.
- 4 Datta S, Dey S, Mukherjee S, Chandra Paul P, Bhattacharyya A, Biswas S, et al. Testicular Fibroma of Gonadal Stromal Origin with Minor Sex Cord Elements, Presenting with Hydrocele. *Rare Tumors.* 2013;5(3):e34.
- 5 Deveci S, Deveci G, Öngürü Ö, Kilciler M, Celasun B. Testicular (gonadal stromal) fibroma: Case report and review of the literature. *Pathol Inl.* 2002;52:326-30.
- 6 Jones MA, Young RH, Scully RE. Benign fibromatous tumors of the testis and paratesticular region: a report of 9 cases with a proposed classification of fibromatous tumors and tumor-like lesions. *Am J Surg Pathol.* 1997;21:296-305.