

Minute pulmonary meningothelial-like nodules simulating a metastatic lung adenocarcinoma: A case report

Aleksandra Karapandžić, Milana Panjković, Živka Eri, Ištvan Klem, Nevena Đukić

SUMMARY

Minute pulmonary meningothelial-like nodules (MPMNs) are relatively rare lesions that located at the pleura or parenchyma of the lung. They are usually found incidentally at autopsy or in surgical specimens. We presented a case of asymptomatic 47-year-old woman with an abnormal shadow in the right upper lung field found by a routine chest X ray. A computed tomography (CT) scan of the thorax revealed a hyperdense subpleural mass, which histologically conformed to adenocarcinoma. A resection of the right upper lobe discovered preponderance of small multiple lesions under the pleura. Microscopically, they were an interstitial nodular proliferation of oval or spindle-shape cells arranged in a *zellenballen* nesting pattern near small veins. Immunohistochemical and cytological analyses confirmed the diagnosis of MPMNs. Coexistence of multiple MPMNs and lung adenocarcinoma can be a differential diagnostic problem due to suspected metastasis of the primary carcinoma. To obtain an accurate diagnosis, the clinical findings should completely conform to histological, immunohistochemical, and cytological ones.

Key Words: Lung Neoplasms; Adenocarcinoma; Paraganglioma, Extra-Adrenal

INTRODUCTION

Minute pulmonary meningothelial-like nodules (MPMNs), previously known as minute pulmonary chemodectomas, are relatively rare lesions (1). These small lesions were first described by Korn et al. in 1960 as multiple minute pulmonary tumors resembling chemodectoma (2). The etiology of these nodules has not been enlightened yet. Histological appearance, ultrastructural findings, and immunological markers suggest their similarity to meningiomas (3). These nodules are generally asymptomatic and are usually found incidentally at autopsy or in surgical specimens resected for unrelated causes (4). The patient population shows a marked female predominance. There appeared to be an association with specific conditions such as cardiac failure, chronic bronchitis and emphysema, thromboembolism and malignancy (3,5). They are uncommon, tumor-like lesions found in the pleura or parenchyma of the lung as solitary or multiple nodules. The location within the pulmonary parenchyma is variable. Microscopically, the tumors consist of small nests of oval to spindle epithelioid cells located in the interstitial tissue of the lung near small veins, without a contact with the air spaces. These nests are organized in the *zellenballen* pattern in paraganglioma (2,5,6). We presented a patient with primary lung adenocarcinoma and the presence of multiple MPMNs. In this case report we described the light microscopic, immunohistochemical, and cytological features of minute pulmonary meningothelial-like nodules.

CASE REPORT

A 47-year-old woman with a history of smoking 20 cigarettes per day for 20 years was referred to our hospital for investigation of an abnormal shadow located in the right upper lung field discovered by a routine chest X ray. The patient was asymptomatic from a pulmonary standpoint and she was in a good general condition.

A computed tomography (CT) scan of the thorax revealed an ovoid, well-circumscribed and homogeneous, hyperdense subpleural mass, about 3 cm in its greatest dimension, in the right upper lobe (S3) (Figure 1). No enlarged hilar or mediastinal lymph nodes were identified. The flexible bronchoscopy

finding was negative for intra-bronchial anomalies. A primary lung carcinoma was suspected.

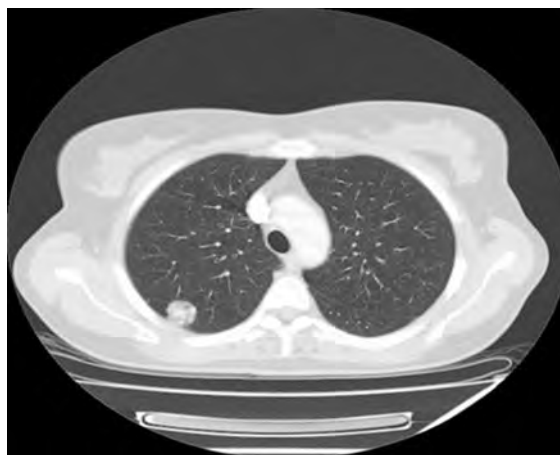

Figure 1. Computed tomography of a patient with peripheral tumor

Video-assisted thoracoscopic surgery was performed with excising the lung parenchyma sample of 5x4x3.5 cm. The tumor was a subpleural, peripheral nodule, 2.3 cm in the longest diameter, relatively well demarcated from the surrounding pulmonary parenchyma, of gray-whitish cut surface with central necrosis. Pleura above the tumor mass was thickened, showing pleural puckering.

The frozen section analysis of the lesion established adenocarcinoma. The tumor was composed of atypical cuboidal to low columnar epithelial cells. The cells formed acinar, papillary, and adenoid formations which showed lepidic growth and increased thickness of the alveolar septa. Fibrovascular stroma indicated focal density infiltration of lymphocytes and plasma cells.

Immunohistochemical analyses of the formalin fixed samples showed positivity of the cells for the thyroid transcription factor-1 (TTF-1) (nuclear positivity) and cytokeratin-7 (CK-7) (membrane positivity).

Arch Oncol 2009;17(1-2):29-31.

UDC: 616.24-006:616-079.4:615.07

DOI: 10.2298/AOO0902029K

Institute of Lung Diseases of Vojvodina, Sremska Kamenica, Serbia

Correspondence to:

MD Aleksandra Karapandžić, Institute of Lung Diseases of Vojvodina, Sremska Kamenica, Serbia

aleksandrakarapandzic@gmail.com

Received: 14.05.2009

Provisionally accepted: 19.05.2009

Accepted: 26.05.2009

© 2009, Oncology Institute of Vojvodina, Sremska Kamenica

The cytology imprint of the tumor indicated a large cluster of uniform cells with ovoid nuclei. The nuclei had delicate smooth membranes and finely reticulated, evenly dispersed chromatin with small nucleoli and a single large nuclear pseudoinclusion. The cell cytoplasm was delicate and contained secretory vacuoles. According to histological, immunohistochemical and cytological appearance of the tumor, the diagnosis of primary lung adenocarcinoma was established.

Hilar and mediastinal lymph node dissection was also performed and all lymph nodes were negative for the presence of the malignant tissue.

A resection of the right upper lobe was performed through a vertical axillary thoracotomy and discovered preponderance of small lesions under the pleura. Grossly, the lesions were multiple, 2-3 mm in its greatest dimension, whitish, well-circumscribed parenchymal nodules, located in the upper right lobe. The nature of these nodules, suggested a metastatic pleural spread.

Microscopically, they represented an interstitial nodular proliferation of small oval or spindle-shape cells arranged in a *zellenballen* nesting pattern near small veins. The cells had weakly eosinophilic cytoplasm with uniformly round to oval nuclei and delicate granular chromatin distribution. The interstitial stromal tissue was organized in fibrous bands (Figure 2).

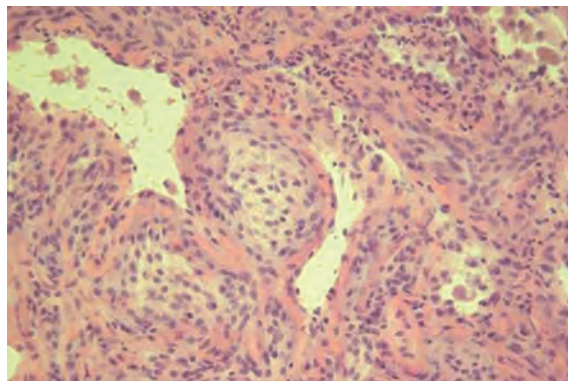


Figure 2. Meningothelial-like nodule: note cells with oval and round nuclei arranged in a somewhat syncytial pattern (HEX40)

Immunohistochemical studies of the described nodules showed positivity of the cells for epithelial membrane antigen (EMA) (membrane positivity), vimentin (cytoplasmic positivity), and progesterone (nuclear positivity) and negative staining for S-100 protein, chromogranin and synaptophysin (Figure 3). The diagnosis of multiple minute pulmonary meningothelial-like nodules was established.

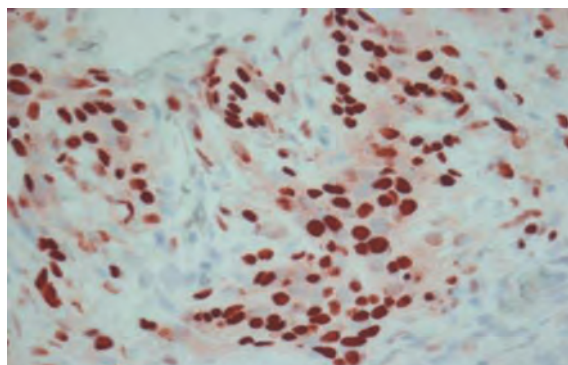


Figure 3. Progesterone nuclear positivity of minute pulmonary meningothelial like nodules cells (x40)

The cytology imprint of the nodules showed nests of uniform oval to slightly spindle and elongated cells with epitheloid appearance, fine delicate granular chromatin, and a small amount of eosinophilic cytoplasm.

DISCUSSION

Improved lung imaging has greatly contributed to easier recognition of MPMNs, previously known as minute pulmonary chemodectoma (7).

These nodules are small (1-3 mm), often multiple and they are more commonly found in women. They are associated with a cardiac disease, chronic bronchitis and emphysema, thromboembolism, and malignancy (3,5). Histologically, the lesions are composed of small nests of epitheloid cells located perivenous in the interstitium of the lung. The cells are oval to spindle, arranged in a *zellenballen* nesting pattern (2,5,6).

In this case report, we described a patient with primary adenocarcinoma of the lung and the presence of multiple MPMNs. Kuroki et al. (8) also reported a patient with MPMNs and lung adenocarcinoma in whom HRCT showed tiny (1-3 mm in diameter) nodules of ground-glass attenuation. Niho et al. (9) stated that MPMNs were seen in 10% patients with lung adenocarcinoma. Mizutani et al. (10) examined 1724 patients undergoing lung resections and their analysis showed that MPMNs were found significantly more often in patients with lung adenocarcinoma than those with other primary pulmonary malignant tumors. In 121 patients they found MPMNs and 92 of them had primary adenocarcinoma.

Immunohistochemical studies showed positivity of cells for epithelial membrane antigen (EMA) and vimentin and negative staining for S-100 protein, chromogranin, and synaptophysin. Suster et al. detected immunohistochemical positivity for EMA and vimentin and negativity for cytokeratin, actin, S-100 protein, CD 34, chromogranin, and synaptophysin (4). Gaffey et al. also found positivity for EMA and vimentin and negative staining for cytokeratin, actin, S-100 protein, and neuron specific enolase (1). Niho et al. discovered a positive staining for EMA and vimentin and negative for S-100 protein synaptophysin and chromogranin (9).

Our immunohistochemical staining also showed positivity for progesterone. Niho et al reported that about half of MPMNs exhibited immunoreactivity for the progesterone receptor⁹. Pelosi et al. confirmed the consistent occurrence of progesterone receptor immunoreactivity in all 6 patients with multiple pulmonary meningothelial nodules detected in surgical specimens of lung carcinomas. They documented that MPMNs are immunoreactive for progesterone receptors, reinforcing their close resemblance to arachnoid cells and meningioma and suggesting a role of sex steroid hormones in their development. In fact, the expression of progesterone receptors in normal arachnoid cells and meningioma is now well established. Although a female preponderance has been reported, the occurrence of these lesions and progesterone receptors immunoreactivity also in males suggest that the receptor status is independent of gender and estrogen control (11).

Spinelli et al. and Gomez et al. described a rare case of meningothelial-like nodules associated with primary pulmonary meningioma (PPM) in the same lung resection. The simultaneous presence of meningioma and meningothelial-like nodules corroborates the unifying hypothesis of their common origin and nature (12,13). PPMs are mostly benign, soft, white, well circumscribed lesions, from 1.5 cm to 4 cm in the greatest dimension, appearing to have preponderance in older women. Histologically, the tumor consists of whorled

nests of spindle to ovoid cells accompanied by psammoma bodies and immunohistochemically it shows positivity for EMA and vimentin and negative or variable expression for keratin, desmin and S-100 protein (14-18). That is the reason why the differential diagnosis of MPMNs includes primary pulmonary meningioma. Also, miliary lung metastases of primary intracranial meningeal tumor could be a differential diagnostic problem (19).

CONCLUSION

The coexistence of multiple MPMNs and primary lung adenocarcinoma is rare in human pathology and until now it has been described only a few times. It can be a differential diagnostic problem because these nodules in the lung on computed tomography (CT) scan of the thorax look like metastases. Microscopically, the differential diagnosis of these nodules includes primary pulmonary meningioma and, rarely, metastasis of primary intracranial malignant meningioma. To establish an accurate diagnosis, the clinical finding should completely conform to histological, immunohistochemical and cytological ones.

Conflict of interest

We declare no conflicts of interest.

REFERENCES

- Gaffey MJ, Mills SE, Askin FB. Minute pulmonary meningothelial-like nodules. A clinicopathologic study of so-called minute pulmonary chemodectoma. *Am J Surg Pathol*. 1988;12(3):167-75.
- Korn D, Bensch K, Liebow AA, Castleman B. Multiple minute pulmonary tumors resembling chemodectomas. *Am J Pathol*. 1960;37:641-672.
- Chung AM, Warnock ML. So-called "minute pulmonary chemodectoma": a tumor not related to paragangliomas. *Cancer*. 1976;37(4):1759-69.
- Suster S, Moran CA. Diffuse pulmonary meningotheliomatosis. *Am J Surg Pathol*. 2007;31(4):624-31.
- Ichinose H, Hewitt RL, Drapanas T. Minute pulmonary chemodectoma. *Cancer*. 1971;28:692-700.
- Aleksić N, Damjanov I. Microscopic lung chemodectomas. *Zentralbl Allg Pathol*. 1972; 116(1):6-9. (German)
- Borcuk AC. Benign tumors and tumorlike conditions of the lung. *Arch Pathol Lab Med*. 2008;132:1141-2.
- Kuroki M, Nakata H, Masuda T, Hashiguchi N, Tamura S, Nabeshima K et al. Minute pulmonary meningothelial-like nodules: high-resolution computed tomography and pathologic correlations. *J Thorac Imaging*. 2002;17(3):227-9.
- Niho S, Yokose T, Nishiwaki Y, Mukai K. Immunohistochemical and clonal analysis of minute pulmonary meningothelial-like nodules. *Hum Pathol*. 1999;30(4):425-9.
- Mizutani E, Tsuta K, Maeshima AM, Asamura H, Matsuno Y. Minute pulmonary meningothelial-like nodules: clinicopathologic analysis of 121 patients. *Hum Pathol*. 2009; in press.
- Pelosi G, Maffini F, Decarli N, Viale G. Progesterone receptor immunoreactivity in minute meningothelioid nodules of the lung. *Virchows Arch*. 2002;440:543-6.
- Spinelli M, Claren R, Colombi R, Sironi M. Primary pulmonary meningioma may arise from meningothelial-like nodules. *Adv Clin Path*. 2000;4(1):35-9.
- Gomez-Aracil V, Mayayo E, Alvira R, Arraiza A, Ramón y Cajal S. Fine needle aspiration cytology of primary pulmonary meningioma associated with minute meningotheliallike nodules. Report of a case with histologic, immunohistochemical and ultrastructural studies. *Acta Cytol*. 2002;46(5):899-903.
- Falleni M, Roz E, Dessy E, Del Curto B, Braidotti P, Gianelli U, et al. Primary intrathoracic meningioma: histopathological, immunohistochemical and ultrastructural study of two cases. *Virchow Arch*. 2001;439:196-200.
- Cesario A, Galetta D, Margaritora S, Granone P. Unsuspected primary pulmonary meningioma. *Eur J Cardio Thorac Surg*. 2002;21(3):553-5.
- Kaleem Z, Fitzpatrick MM, Ritter JH. Primary pulmonary meningioma. Report of a case and review of the literature. *Arch Pathol Lab Med*. 1997;121(6):631-6.
- Moran CA, Hochholzer L, Rush W, Koss MN. Primary intrapulmonary meningiomas: A clinicopathologic and immunohistochemical study of ten cases. *Cancer*. 1996;78(11):2328-33.
- Ueno M, Fujiyama J, Yamazaki I, Uchiyama T, Ishikawa Y, Satoh Y. Cytology of primary pulmonary meningioma. Report of the first multiple case. *Acta Cytol*. 1998;42(6):1424-30.
- Tasić M, Vuković R, Simić M, Budimlija Z. Meningeal tumor with miliary lung metastases- Case report. *Arch Oncol*. 1998;6(Suppl.2):151.