



Complete mesocolic excision with central supplying vessel ligation – new technique in colon cancer treatment

Tomislav Petrović, Zoran Radovanović, Milan Breberina, Brane Gavrančić

SUMMARY

Arch Oncol 2010;18(3):84-5.

UDC: 616.348-006:615-085

DOI: 10.2298/AOO1003084P

Oncology Institute of Vojvodina, Sremska Kamenica

Correspondence to:

Doc. dr. sci. med. Tomislav Petrović,
Oncology Institute of Vojvodina,
Institutijski put 4,
21204 Sremska Kamenica

petrovic.tomislav@onk.ns.ac.rs

Received: 12.07.2010

Provisionally accepted: 11.08.2010

Accepted: 31.08.2010

The basis of complete mesocolic excision represents the continuation and the conceptual idea of the total mesorectal excision of rectum (TME) which was described and promoted by R. J. Heald in 1983, and the point is to make the excision of the contaminated portion of the colon with the tumor in his visceral (embryonic) sheath without any damages of the central ligature of supplying vessels and preservation of the autonomous nervous system. According to this concept, colon and rectum, in their embryonic genesis, were belted on both sides with visceral fascia, as an envelope and through mesocolon, there was vascular and lymphatic drainage, while the ligature at the source of the vascular pedicle provided the removal of the largest number of lymphatic nodes. Surgical, sharp dissection, i.e. separation of visceral fasciae of the colon from the parietal peritoneum without any damage and total mobilization of the entire mesocolon with ligation in the very source of the supplying blood vessels. The scope of surgical mobilization of mesocolon is defined by the tumor localization. Literature provides numerous data supporting the fact that such technique enables the reduction in number of local recidives from 6.5% to 3.6% and increase of the five-year survival from 82.1% to 89%. CME technique provides optimal treatment of the colon cancer.

Key words: Colonic Neoplasms; Mesocolon; Colorectal Surgery; Blood Vessels; Ligation

© 2010, Oncology Institute of Vojvodina,
Sremska Kamenica

SURGICAL ANATOMY OF THE COLON

Surgically and anatomically, colon is divided into right and left, and the basis for this classification is its specific vascularisation. This classification is important for surgeons, especially in respect to resection procedures. Right colon is vascularized by the superior mesenteric artery (AMS), i.e. caecum, ascending colon and 2/3 of the transversal colon. Left colon includes the back third of the transversal colon, descending and sigmoid colon all the way to rectosigmoid traverse. The left colon is vascularized by the bottom, mesenteric artery (AMI). The greatest practical significance lies in the fact that the vascular system of the upper and the bottom mesenteric artery are not separated. They are interlinked by the wide anastomosis between the middle and left colic artery. Besides that, the middle colic artery, in its passing through the mesocolon of transversum may vary like the hands on the clock. A detailed knowledge of the colon vascularization is necessary for safe performance of resection procedures. Thus, conservation of one of main arterial branches of the upper, i.e. bottom mesenteric artery satisfies the need for vascularization of the right, i.e. left colon. For good vascularization of the colon, it is important to preserve the marginal arteries of the colon (MAC) (1, 2).

Besides the fact that the knowledge of the colon vascularization is very important from the surgical point of view, it is also important to be familiar with anatomic relations of the fixed and free portions of the colon. Along entire circumference, free parts of the colon provide serous sheath, which represents the greatest guaranty of anastomosis' scarring, i.e. after resection. On the contrary, the fixed parts of the colon (ascending and descending colon) in the area of the back wall, do not have serous sheath, which questions the sufficiency of the stitch line of these parts of the colon wall. This represents an older understanding of the visceral peritoneum position at the fixed parts of the colon. However, a group of authors from Erlagen, with Hohenberger as their leader, states that the entire colon with the accompanying mesocolon is covered as the "envelope" by the visceral fascia, which enables its sharp total excision, complete mesocolic excision (CME). This concept is practically the consequence of the Heald's total

mesorectal excision of rectum, TME (3), which is based on high ligation A and VMI in entering of the vascular area between the endorectal (visceral fascia) and parietal fascia (endopelvic fascia) which ends by intersecting the Denonvilliers' fascia in the front and intersecting Waldeyer's fascia at the back. Practically, Hohenberger believes that endorectal fascia continues to the left on the visceral fascia of the mesocolon and that it ends in the area of the pancreas' tail and spleen's hilus, while, the other part of the endorectal fascia to the right continues to the fascia of caecum and ascending mesocolon and ends central intraomental area at the source of AMS. For successful CME, a high ligation at the source of the vessels is necessary, and practically, the elevation of the entire mesocolon, i.e. both the left and the right flexure with previous separation of the omentum from the transversal colon. After elevation of the mesocolon, right or left hemicolectomy with preservation of the appropriate mesocolic arcades is performed depending on the tumor localization. For the right hemicolectomy, it is necessary to approach to transversum mesocolon, to identify the colica media, colica dextra artery, and the ileocolic artery. This implies the previous elevation of duodenum by Kocher maneuver. This technique is not impossible but its performance is very difficult in obese patients and it is believed that, in our conditions, it is not possible to include it as the standard procedure, due to insufficient education of the surgical personnel. However, in highly specialized institutions and with proper education, it can be implemented. In my opinion, the situation with the performance of left hemicolectomy is much better because identification of AMI is not difficult but a very good technique is necessary for finding the mesocolic fascia as a whole and for its intact excision because only in this way, the number of local recidives is reduced. The performance of CME gives mortality of up to 3.1% (3- 5). Venous and lymphatic colon drainage. Colon veins follow the arteries. Venous blood flows into the upper and lower mesenteric veins which are included into the portal vein. Lymphatic drainage of colon goes through three levels of lymph glands. The first level are the epiploic lymph glands. They are located next to the wall of the colon. The middle level constitute intermedial (paracolic) lymph

glands, which are located next to the branches of the upper and the bottom mesenteric arteries. The third level are central lymph glands. They are separated for the right, i.e. left colon and they are practically the most significant ones. Metastases in the central lymph glands, in most of the patients with the colon carcinoma, represent inoperable cases. This applies, especially for the central lymph glands of the left colon, and today they are marked as M1. Central lymph glands of the right colon are located next to the source of AMS. In the area of the lower edge of duodenum, in about 4% of cases, there are positive lymph glands, but in the area of processus uncinatus in about 5% of cases. Central lymph glands of the distal third of the colon transversum are located in the area of left flexure, follow the upper edge of pancreas and the lienalis artery and end in spleen's hilus. This is the reason why some surgeons insist on splenectomy with resection of the pancreas' tail in resections due to distal transversum and lineal flexure carcinoma. Central lymphatic nodes of the descending and sigmoid colon are located in the area of the AMS source and along the aorta. Those lymph glands are not difficult for removal. This is why, prior to resection of the left colon, it is necessary to ligate AMS in the central position. It should be mentioned that the area of the large omentum and gastrocolic ligament are not places of direct lymphogenetic spread of carcinoma. However, both of them may be secondarily included in advanced carcinoma (5-7).

SURGICAL CME TECHNIQUE

Surgical concept of CME represents sharp separation of the undamaged visceral fascia of mesocolon from parietal fascia of peritoneum and the end goal is mobilization of mesocolon and the approach to the appropriate vascular bundle. The scope of surgical intervention depends on localization of the tumor itself (Figure 1). In case that the tumor is located in the right colon next to caecum and ascending colon, it also implies the elevation of duodenum and the head of pancreas (Kocher maneuver) and access to the upper mesenteric vein and artery and its branches (5, 7).

For tumors of the left colon, mobilization of sigma and descending colon is necessary, total separation from the parietal peritoneum, urethra, testicular or ovarian blood vessels, as well as separation from the kidney fat tissue. Descending of the lineal flexure and separation from the lower edge of pancreas is performed. In some cases, if the lymph glands in the spleen hilus area are enlarged, the spleen and the tail of pancreas are removed.

LYMPH GLANDS DISSECTION

Colon carcinoma first spreads through pericolic lymph glands but not more than 8 cm from the primary tumor, and then it spreads along the accompanying blood vessels and ends in central lymph glands, which are located in the root of the vascular bundle (Figure 2).

For colon, ileocolic and middle colic arteries are the most significant. Right colic artery is only in 10% to 15% of cases a direct branch AMS, while in other cases it can have a common stem with middle or ileocolic artery, although rarely it may be entirely missing. In 5% of cases, carcinoma in the area of hepatic flexure gives metastases in the area of head of pancreas, and in 4% of cases, along the epiploic arcade. Thus, it is necessary to free the great curve of stomach in the length of 10cm to 15cm in right hemicolectomy (7). In case of carcinoma in the area of transversal colon, it is necessary to determine which artery is predominant in vascularization, whether it is middle colic or left colic. According to this, resection should be subordinated

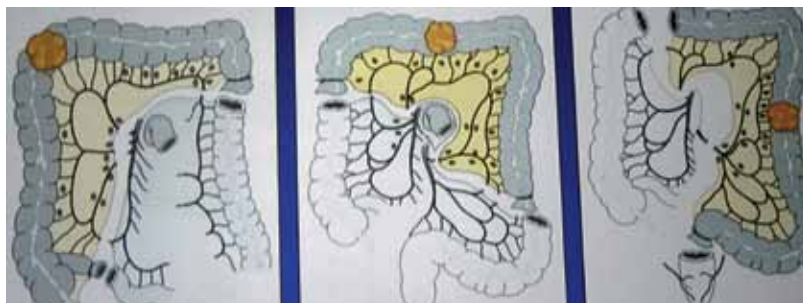


Figure 1. Plane of surgical resection according to tumor localization

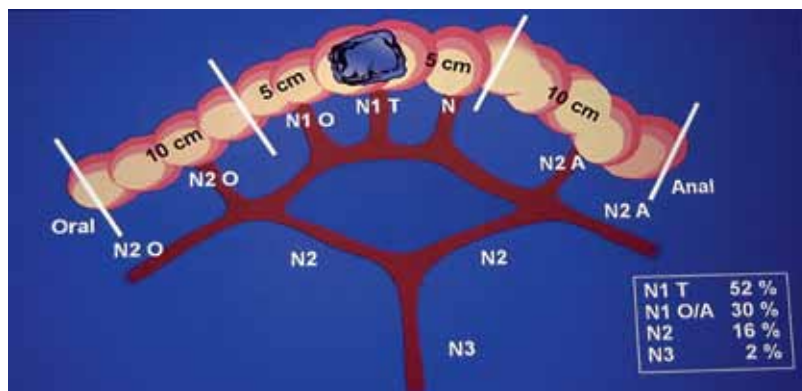


Figure 2. Plane of surgical resection according to metastatic lymph nodes

to widened right hemicolectomy, i.e. left hemicolectomy, in order to obtain adequate lymphadenectomy. Transversal colon surgeries, per this concept, are not radical enough. Tumors of descending and sigmoid colon are metastasizing towards bottom mesentery artery (8).

CONCLUSION

On the basis of the above described, it is my opinion that the CME concept itself has good bases in embryonic plan but that there is still a problem of increased mortality and that it is not possible to entirely make a parallel with TME, which became a standard in treatment of cancer of end part of colon.

Conflict of interest

We declare no conflicts of interest.

REFERENCES

- 1 Goliger JC. Surgery of the Anus, Rectum, and Colon, 3d. ed. London: Bailliere; 1975.
- 2 Wendel T. Colon Anatomy. 5. International Symposium and Workshop. Advanced Course Colorectal surgery. Erlangen. May 10-12, 2010.
- 3 Heald RJ. The Holy Plane of rectal surgery. *JR Soc Med.* 1988;81:503-8.
- 4 Hohenberger W. Complete mesocolic excision – CME. International Symposium and Workshop. Advanced Course Colorectal surgery. Erlangen. May 10-12, 2010.
- 5 Hohenberger W, Weber K, Matzel K, Papadopoulos T, Merzel S. Standardized surgery for colon cancer: complete mesocolic excision and central ligation-technical notes and outcome. *Colorectal Dis.* 2009;11(4):354-64.
- 6 Toyota S, Ohta H, Anazawa S. Rationale for extent of lymph node dissection for right colon cancer. *Dis Colon Rectum.* 1995;38:705-11.
- 7 Van Damme JP, Bonte J. The more exceptional right colic artery. In: Van Damme J-P, Bonte J, editors. *Vascular Anatomy in Abdominal Surgery.* Stuttgart, New York: Gorg Thieme; 1990. p. 53.
- 8 Hohenberger W, Weber K, Matzel K. Lymphadenectomie bei Tumoren des unteren Gastrointestinaltrakts. *Chirurg.* 2007;78:214-25.