

Gestational choriocarcinoma with hemorrhagic pleural effusion

Biljana Lazović¹, Vera Milenković²

SUMMARY

Arch Oncol 2010;18(3):86-7.

UDC: 618.3-06:616-006:616.25-003.215
DOI: 10.2298/AOO1003086L

¹University Hospital Zemun, Zemun, Serbia, ²Medical School, Institute of OB/Gyn, Clinical Center of Serbia, Višegradska 26, Belgrade, Serbia

Correspondence to:
Biljana Lazović, Milutina Milankovica
122, 11070 Belgrade, Serbia

lazovic.biljana@gmail.com

Received: 05.06.2010

Provisionally accepted: 05.07.2010

Accepted: 14.07.2010

© 2010, Oncology Institute of Vojvodina,
Sremska Kamenica

Gestational trophoblastic disease (GTD) consists of a spectrum of disorders that are characterized by an abnormal proliferation of trophoblastic tissue. By virtue of their high vascularity and affinity of trophoblast for blood vessels, metastases often occur early and the most common site of such metastases is the lung. We described a case of a 34-year-old patient with pain in the left half of the chest, occasional, brief hemoptysis, and amenorrhea occurring in the period of 3 months. This presentation highlights the importance of analysis of HCG in the pleural puncture, for quick diagnosis and timely treatment.

Key words: Gestational Trophoblastic Neoplasms; Choriocarcinoma; Neoplasm Metastasis; Pleural Effusion, Malignant

INTRODUCTION

Gestational trophoblastic neoplasm (GTN) represents a spectrum of pathologic and clinical alterations, ranging from molar pregnancy to metastatic gestational trophoblastic neoplasm (1). Metastatic tumors develop after a complete molar pregnancy, but they are more common after non-molar pregnancies. The most common sites of GTN metastases are the lungs, vagina, pelvis, liver, and brain. Trophoblastic tumors are highly vascular and prone to severe hemorrhage, either spontaneous or during biopsy. Patients with pulmonary metastases may have hemoptysis, dyspnea, chest pain, bloody effusion, and hypovolemia. Because respiratory symptoms and a radiological finding may be dramatic, the patient may be thought to have primary pulmonary disease (2, 3). Regrettably, the diagnosis of GTN may be confirmed only after thoracotomy has been performed, particularly in patients with a non-molar antecedent pregnancy. In patients with GTN, gynecological symptoms are sometimes ignored (4).

CASE REPORT

A 34-year-old female patient was admitted for complaints of left pleuritic chest pain, cough with occasional hemoptysis, subfebrile temperature (the highest 38°C) of three months duration. She also had amenorrhea for two months. Her menstrual history was normal and the previous pregnancy had been term delivered. Clinical examination showed a mildly anemic young woman without jaundice, or significant lymphadenopathy. She had dull note on percussion on the left side. Breath sounds and vocal resonance was decreased on the same side. Liver and spleen were not palpable.

A chest radiograph on hospital admission revealed a large well-circumscribed mass in the left lower zone, which subsequently enlarged invading the pleura (Figure 1). Pleural fluid was hemorrhagic and malignant cells were not identified. Pleural biopsy suggested metastatic choriocarcinoma. Pleural fluid and urine HCG were 800,000 IU/L and 4500,000 IU/L respectively as detected by slide latex agglutination test. Blood count was in the normal range. The USG of pelvis and a detailed gynecological examination showed a soft cystic mass around 6 cm in the posterior fornix on the left side.

The patient was prepared for chemotherapy and irradiation. First dosage of vincristine, methotrexate, and chlorambucil was administered. In the meantime, she developed a left sided hemiplegia following headache. MRI was reported as hemorrhagic tumor in left parietal lobe with significant

mass effect and surrounding edema. The general condition deteriorated and the rapid reaccumulation of pleural fluid necessitated intercostal tube thoracostomy. The patient died on the 14th hospital day.

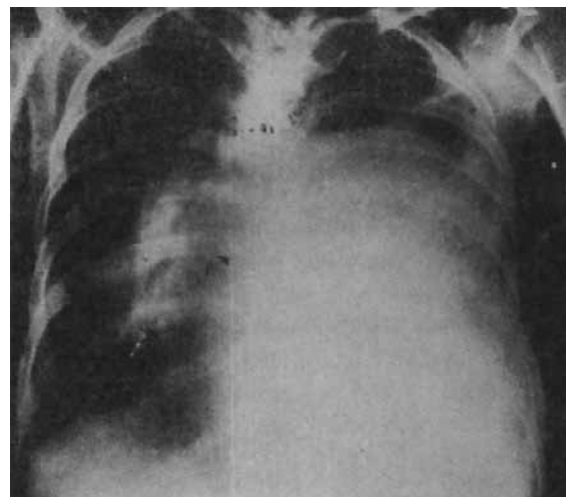


Figure 1. Chest radiograph showing a large left pleural effusion

DISCUSSION

Choriocarcinoma is a malignant tumor of the trophoblast and generally follows an identifiable gestational event. Approximately 50% of choriocarcinomas occur after a molar pregnancy, 25% after an abortion, and 22% after a normal pregnancy (5). Metastatic gestational trophoblastic neoplasm has a propensity for early vascular invasion and dissemination. Patients may present with signs and symptoms of bleeding from metastases such as hemoptysis, hepatic rupture, or acute neurological deficits (4). GTN is extremely responsive to chemotherapy. Therefore, chemotherapy is the main modality of treatment in patients with GTN even in its metastatic forms (4). Early recognition of GTN will maximize the chances of curing with chemotherapy. Clinicians should be aware of the possibility of GTN in any reproductive-aged woman with bizarre central nervous system symptoms, gastrointestinal, pulmonary symptoms, or radiographic evidence of metastatic tumor of unknown primary origin.

The initial roentgenographic presentation in our patient was a large pulmonary mass, which subsequently invaded the pleura, giving rise to a massive

effusion. Pleural biopsy in this patient prompted us to look for HCG not only in urine but also in pleural fluid.

We would like to emphasize that detection of HCG in pleural fluid and urine/serum form part of the diagnostic work of such female patients with hemorrhagic pleural effusion. This is a simple, non-invasive, quick bedside procedure and helps in the early diagnosis and institution of prompt therapy, which is so crucial for prognosis.

Our patient had poor prognosis, metastatic gestational neoplasia by virtue of her antecedent term pregnancy and symptoms of over three months. Hammond et al (6) distinguished a metastatic gestational neoplasia of poor prognosis by the presence of one or more of the following: urinary HCG levels elevated to more than 10,000 IU/L or serum HCG levels more than 40,000 mIU/L (B HCG RIA), symptoms of malignancy present for longer than four months, brain or liver metastases, unsuccessful previous chemotherapy and antecedent term pregnancy. It appears that detection of HCG in pleural fluid in metastatic gestational neoplasia can be added up to this list indicating poor prognosis.

Another factor, which tilted the clinical course against our patient, is the development of brain metastases, while she was under chemotherapy. The prognosis in patients who develop cerebral metastases while under chemotherapy has been found to be worse than in patients initially with such metastases. Aggressive multi-agent chemotherapy with adjuvant irradiation or surgical therapy forms the cornerstone of management of poor prognosis metastatic gestational trophoblastic neoplasm (6, 7). However, such combined modality treatment was not possible in our patient even though chemotherapy and irradiation was initially planned.

Conflict of interest

We declare no conflicts of interest.

REFERENCES

- Balagopal PG, Pande M, Chandramohan K, Somanathan T, Kumar A. Unusual presentation of choriocarcinoma. *World J Surg Oncol*. 2003;1.
- Berkowitz RS, Goldstein DP. The management of molar pregnancy and gestational trophoblastic tumors. In: Knappe RC, Berkowitz RS, editors. *Gynecological Oncology*. 3rd ed. New York: McGraw-Hill; 1993. p. 328-38.
- Ghaemmaghami F, Sohrabvand M, Ayatollahi H, Modarres M. Successful treatment of colon metastatic patient with GTN. *J Obstet Gynecol*. 2005;5(25):735-7.
- Newlands ES. The management of recurrent and drug-resistant gestational trophoblastic neoplasia (GTN). *Best Prac Res Clin Obstet Gynecol*. 2003;17(6):905-23.
- Ghaemmaghami F, Behtash N, Memarpour N, Soleimani K, Hanjani P, Hashemi FA. Evaluation and management of brain metastatic patients with high-risk gestational trophoblastic tumors. *Int J Gynecol Cancer*. 2004;14:966-71.
- Hammond CB, Borchert LG, Tyrey L, Creasman WT, Parker RT. Treatment of metastatic trophoblastic disease: Good and poor prognosis. *Am J Obstet Gynecol*. 1973;115:451-7.
- Surwit EA, Hammond CB. Treatment of metastatic trophoblastic disease with poor prognosis. *Obstet Gynecol*. 1980;55:565-70.