

Testicular (gonadal stromal) fibroma: case report

Dragana Tegeltija, Aleksandra Lovrenski, Milana Panjković, Živka Eri, Ištvan Klem

SUMMARY

Arch Oncol 2012;20(1-2):26-7. UDC: 616.68-006
DOI: 10.2298/AOO1202026T
Center for Pathology, Institute for Pulmonary Diseases of Vojvodina, Sremska Kamenica, Serbia
Correspondence to: Aleksandra Lovrenski, Center for Pathology, The Institute For Pulmonary Diseases of Vojvodina, Put dr Goldmana 4, 21204 Sremska Kamenica

Testicular fibroma is a rare benign tumor of gradual growth, usually in the third and fourth decade, in the form of a hypoechogenous nodule with clear boundaries and is usually not accompanied by hormonal abnormalities. Metastasis and recurrence of disease were not noted. A 40-year-old male sought medical attention due to pain in the lower back that spread to the pubic bones and the groin. During physical examination, a painless nodule with clear boundaries was palpated in the right testicle, and the ultrasonographic examination revealed hypoechogenic zone with vague boundaries of about 10 mm in diameter. Standard biochemical analyses of blood and urine tests and tumor markers (CEA, CA 125, CA 19-9, AFP and β HCG) were within the physiological limit. Histopathologic analysis set a diagnosis of testicular fibroma. The absence of sex cords in the tumor tissue made it possible to diagnose the patient using standard staining methods, but in cases where these elements can be histologically verified, immunohistochemical analysis should be introduced into a routine diagnostic algorithm.

ajalovrenski@yahoo.com **Key words:** Testicular Neoplasms; Fibroma; Diagnosis; Histological Techniques

Received: 23.05.2012
Provisionally accepted: 22.06.2012
Accepted: 28.06.2012

© 2012, Oncology Institute of Vojvodina, Sremska Kamenica

INTRODUCTION

Testicular fibroma (TF) is a rare benign tumor which, according to the WHO, belongs to the fibroma-thecoma group. Literature records only 25 cases, occurring predominantly in the third and fourth decade of life (1). The tumor grows unilaterally, gradually, sometimes accompanied by pain (2). Tumor growth is neither accompanied by hormone disorders, nor have there been cases of metastasis or disease relapse (3).

CASE REPORT

A 40-year-old male sought medical attention due to pain in the lower back that spread to the pubic bones and the groin. During physical examination, a painless nodule with clear boundaries was palpated in the right testicle, of about 10 mm in diameter. Standard biochemical analyses of blood and urine tests and tumor markers (CEA, CA 125, CA 19-9, AFP and β HCG) were within the physiological limit. The ultrasonographic examination revealed a hypoechogenic zone with vague boundaries of about 10 mm in diameter, of unclear etiology with numerous microcalcifications that were observed in both testicles. On the sixth day after admission, under general, endotracheal anesthesia, the right testicle and the funiculus was removed. The testicle together with the membranes measured 40 x 25 x 20 mm, and the funiculus was 80 mm in length. The capsule was smooth, greyish and shiny. At the cross section, in the central part of the testicle there was a nodule with clear boundaries measuring 14 x 10 mm. The nodule was whitish, hard and was prominently above the surface of the cross section. There were no signs of necrosis and hemorrhage. The funiculus was of usual appearance. Microscopic examination matched the described nodule to a tumor outside the capsule with clear boundaries. The tumor parenchyma was built of beams of hyalinised binders with rare uniform fibers and blended capillaries lined with flattened endothelial cells. Mitosis, necrosis and hemorrhage were not present. Hyaline thickening was observed with the base membrane of the surrounding compressed tubules, and the tubule was lined with Sertoli cells (Figure 1). Microcalcifications were found in the funiculus and the rete testis. The absence of sex cords in the tumor tissue made it possible to set diagnosis using the standard H&E, and special Mallory and Gomory meth-

ods of staining (Figures 2 and 3) without using immunohistochemistry. The patient was discharged and felt well for the next three months.

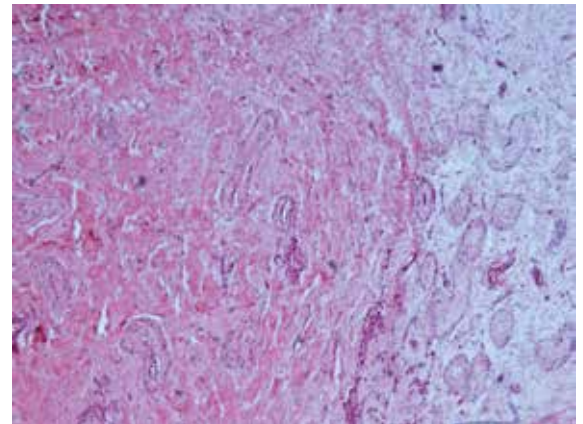


Figure 1. Left: Tumor parenchyma build of hyalinised binders and capillaries with flattened endothelial cells. Right: Surrounding testicular parenchyma with compressed tubules, (H&E x 5)

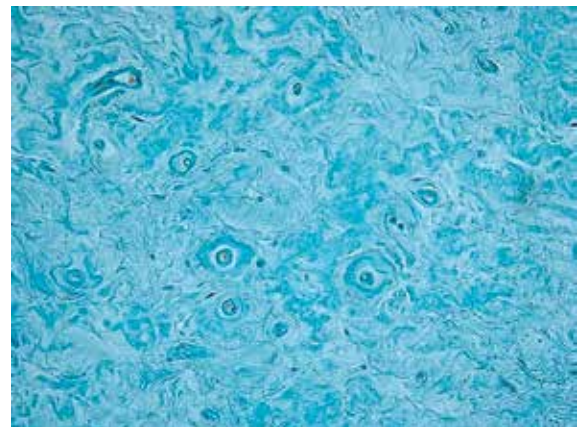


Figure 2. Tumor parenchyma: hyalinised binders and capillaries with hyaline thickening of the wall, (Mallory x 20)

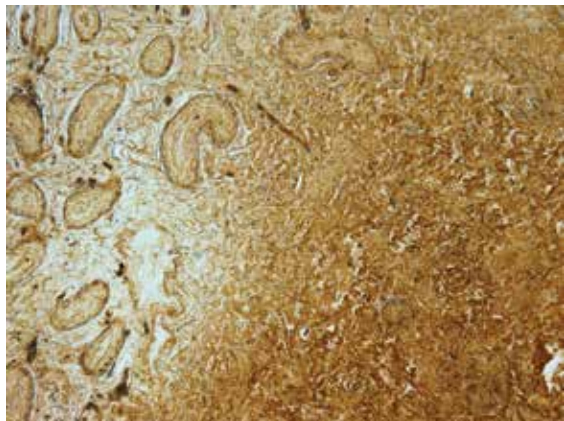


Figure 3. Left: Normal testicular parenchyma. Right: Tumor parenchyma with hyalinised binders and capillaries, (Gomory x 5)

DISCUSSION

Fibroma-thecoma is a type of sex cords and stroma tumor. These tumors constitute 4-6% of all testicular tumors in adult males (1). Testicular fibroma has been given various names in literature: unclassified sex cord-stromal tumor, benign gonadal stromal tumor, spindle-shaped fibroblast type, testicular stromal tumor with myofilaments, and more recently as gonadal stromal fibroma (4, 5). The youngest patient diagnosed with the TF was only 2 years old (6), and the oldest was 67 (2). The average age of patients with TF is 31 (2). In our case, the patient denied any infection or trauma in the area of the testicle which is consistent with the data from Deveci et al. (3). With our patient, there was no pain in the testicle, increase in tumor markers or pathological findings in the analysis of blood and urine, the same as with Pinieux et al, Renshaw et al, and Allen et al. (7, 5, 8). Only a small number of cases of TF grew rapidly and were accompanied by pain (2, 3). The tumor is most often localized in the central part of the testicular parenchyma having no contact with the tunic albuginea. Microscopically, it is composed of spindle cells arranged in a swirling or fasciculus formation. These cells are separated by fibrocollagen, partly by hyalinised stroma with many capillaries. Mitosis are rare, 1 to 2 per 10 HPF (high power field), although, even 4 mitosis per 10 HPF are tolerated (2). Calcifications in this tumor are rare, but Deveci et. al described a case of TF with numerous calcifications (3). Nearby testicular parenchyma may be unchanged, with hypospermatogenesis, or the tubule can be covered with Sertoli cells only (2, 9). In a series of nine cases of TF, published by Jones, Young and Scully the tumor in question was one of clear boundaries, rarely in capsule, of yellowish-whitish color, with no hemorrhage and necrosis, with a diameter of 0.4 to 5 cm, the average size of 2.6 ± 0.4 cm (2).

Immunohistochemical expression for vimentin, actin, desmin, S-100 protein, CD 4, cytokeratin (CK) and MIC 2 is present in most tumor cells (8-10). Pinieux et al. noted the presence of a small number of sex cord elements in two cases of TF using CD99/MIC2 (Sertoli and Leydig cells) and anti-inhibin (Sertoli, and Leydig granulosa cells) (7). Nistal et al. pointed out that the TF in their case was negative for keratin, S-100 protein and factor XIIIa, and therefore suggests that this tumor stems from peritubular myoid cells (10). The differential diagnosis includes: leiomyoma, neurofibroma, solitary fibrous tumor, and fibrosarcoma. When it comes to setting a definite diagnosis, the application of immunohistochemical methods plays an important role. TF and leiomyoma are positive for vimentin, desmin and smooth muscle

Actin. Aiding the differential diagnosis of these two tumors is the sex cord finding and a positive reaction to MIC2 and inhibin in the TF. Neurofibroma is positive for S-100 protein, but negative for Actin, desmin, MIC2 and anti-inhibin. Solitary fibrous tumor is positive for CD34, whereas no TF expression was detected for this antibody. Fibrosarcoma is made up of tumor cells with prominent atypia, along with numerous mitotic figures (2). Jones and Miettinen monitored TF patients for 3 and 96 months. There were no records of recurrences or metastases of the tumor in their patients (2,9).

Given that the testicular fibroma may or may not contain elements of sex cords, and bearing in mind that the testicular stroma is of the same origin as ovarian stroma, TF is a counterpart to ovarian fibroma, according to its histomorphological and immunohistochemical features (2). In our patient, as well as with Deveci, no elements of sex cords have been registered, thus it was possible to set the differential diagnosis via standard H&E staining method (3).

CONCLUSION

Asymptomatic and gradual growth of the nodule in the testicle and its hypoechogenic ultrasound image suggest the diagnosis of TF. The absence of sex cords in the tumor tissue made it possible to set a diagnose using standard staining methods, which cuts the costs of performing immunohistochemical analysis and determining the testicular tumor marker, but in the cases where these elements can be histologically verified, these diagnostic methods should be introduced into a routine diagnostic algorithm.

Conflict of interest

We declare no conflicts of interest.

REFERENCES

- 1 World Health Organization Classification of Tumours. IARC. Tumours of the testis and paratesticular tissue. Lyon; 2004. p. 257.
- 2 Jones MA, Young RH, Scully RE. Benign fibromatous tumors of the testis and paratesticular region: a report of 9 cases with a proposed classification of fibromatous tumors and tumor-like lesions. *Am J Surg Pathol.* 1997;21:296-305.
- 3 Deveci S, Deveci G, Öngürü Ö, Kilicler M, Celasun B. Testicular (gonadal stromal) fibroma: Case report and review of the literature. *Pathology International.* 2002;52:326-30.
- 4 Nistal M, Martinez-Garcia C, Paniagua R. Testicular fibroma. *J Urol.* 1992;147:1617-9.
- 5 Renshaw AA, Gordon M, Corless CL. Immunohistochemistry of unclassified sex cord-stromal tumors of the testis with a predominance of spindle cells. *Mod Pathol.* 1997;10:693-700.
- 6 Collins DH, Symington T. Sertoli-cell tumor. *J Urol.* 1964;36:52-61.
- 7 Pinieux G, Glaser C, Chatelain D, Perie G, Flam T, Vieillefond A. Testicular fibroma of gonadal stromal origin with minor sex cord elements- clinicopathologic and immunohistochemical study of 2 cases. *Arch Pathol Lab Med.* 1999;123:391-4.
- 8 Allen PR, King AR, Sage MD, Sorrel VF. A benign gonadal stromal tumor of the testis of spindle fibroblastic type. *Pathology.* 1990;22:227-9.
- 9 Miettinen M, Salo J, Virtanen I. Testicular stromal tumour: ultrastructural, immunohistochemical, and gel electrophoretic evidence of epithelial differentiation. *Ultrastruct Pathol.* 1986;10:515-28.
- 10 Nistal M, Puras A, Perna C, Guarch R, Paniagua R. Fusocellular gonadal stromal tumour of the testis with epithelial and myoid differentiation. *Histopathology.* 1996;29:259-64.