

SPECT-CT in myocardial perfusion scintigraphy

Marina Garcheva-Tsacheva

SUMMARY

Arch Oncol 2012;20(3-4):132-5.

UDC: 616.13:616-72:615.849:681.3

DOI: 10.2298/AOO1204132G

Department of Nuclear Medicine,
Medical University-Sofia

Correspondence to:
Marina Garcheva-Tsacheva, Department
of Nuclear Medicine, Medical University-
Sofia, 1, "G.Sofijski" Sofia 1431, 1, "G.
Sofijski" Sofia 1431
marina.garcheva@gmail.com

Received: 16.08.2012

Accepted: 21.08.2012

© 2012, Oncology Institute of
Vojvodina, Sremska Kamenica

Presented at the 1st Serbian
Symposium on Hybrid Imaging and
Molecular Therapy, Novi Sad, Serbia,
April 23-25, 2012

The main application of SPECT-CT in Nuclear Cardiology is for attenuation correction AC. The nonuniform attenuation, scatter and distance-dependant resolution are confounding factors inherent in SPECT imaging. The specific effects on myocardial images, due to subdiaphragmatic, or to the breast tissue attenuation present as irreversible or reversible false positive defects – artifacts. They can decrease the specificity of the examinations and increase the inconclusive interpretations. SPECT-CT permits fast creation of attenuation maps (within seconds). The AC improves the diagnostic accuracy, the normalcy rate in patients with low probability of coronary artery disease (CAD), the viability detection and the detection of stenoses in multiple vascular distributions. In order to avoid AC generated artifacts an adequate quality control is mandatory: of body truncation, of patient's motion, of accurate registration of attenuation maps and emission data. Incorrect fusion of SPECT and CT images can cause serious mistakes. The reduction of equivocal interpretations offers additional benefit in the use of stress-only imaging for patients with low pretest likelihood of CAD, or rest-only imaging in patients with acute chest pain. The review of low-dose CT scan adds important unexpected findings of concomitant extracardiac pathology (e.g. pleural and pericardial effusions, mediastinal masses and pulmonary lesions). Recent equipment development made it possible to introduce, in clinical practice, hybrid SPECT/CT cameras that perform not only CT AC but which also acquire high quality CT-images for the purpose of coronary calcium scoring and CT coronary angiograms. The integration of nuclear cardiac imaging and cardiac CT combines in one setting the assessment of coronary anatomy and perfusion and provides determination of the physiologic significance of lesions.

Key words: Tomography, Emission Computed, Single-Photon; Myocardial Perfusion Imaging; Diagnostic Imaging; Coronary Artery Disease

INTRODUCTION

The main application of SPECT-CT in Nuclear Cardiology is for attenuation correction AC. The nonuniform attenuation, scatter and distance-dependant resolution are confounding factors inherent in SPECT imaging. The specific effects on myocardial images, due to subdiaphragmatic, or to the breast tissue attenuation present as irreversible or reversible false positive defects – artifacts (Figure 1). They can decrease the specificity of the examinations and increase the inconclusive interpretations. Gated images are not always helpful, especially when the kinetic disturbances have been lost because of the late stress registration. In this case the real defects could be taken as artifacts and the false negative interpretations decrease the sensitivity of examinations. SPECT-CT permits fast creation (within seconds) of attenuation maps by low-dose CT scan.

The image quality following attenuation correction for myocardial perfusion images is superior (with better resolution and more details) probably

because of the iterative reconstruction, used instead of filtered back projection. The readers should be aware of differences in the appearance of normal corrected (AC) and uncorrected (NAC) myocardial perfusion images (MPI). The septal region looks more prominent and equal to the lateral wall, because of the improved homogeneity of AC images (1). The apical thinning is more visible and should not be confused with true perfusion defect. The right ventricle appears more prominent in the absence of right ventricular hypertrophy (2).

A specific database has to be used for quantification, because of the differences in normal corrected and uncorrected stress MPI (3). It should be also tracer specific for ²⁰¹Tl and ^{99m}Tc-images (4).

According to the earliest investigators, the AC improved the specificity by 34% and the normalcy rate by 10%. The number of detected significant stenoses increased on AC MPI (5). The more recent studies found increased specificity in all 3 coronary territories by 23%, and mild increase in sensitivity by 4% (6). Not only patients with body mass index (BMI) > 30, but also lean patients benefit with regard to the specificity of examinations (7). The viability detection in an attenuated territory might be very important for the therapeutic decision. An improvement by 20% was achieved for the detection of viable myocardium in patients with previous myocardial infarction and left ventricular dysfunction (a ²⁰¹Tl study, 8). Besides the inferior wall in case of RCA (right coronary artery) occlusion, neighboring areas like postero-septal and infero-lateral regions were interpreted with higher accuracy for viability on AC images, because of the increased relative count density (9).

The AC needs a very strong quality control. The wrong acquisition of each component (CT, or SPECT), or the wrong fusion may create attenuation

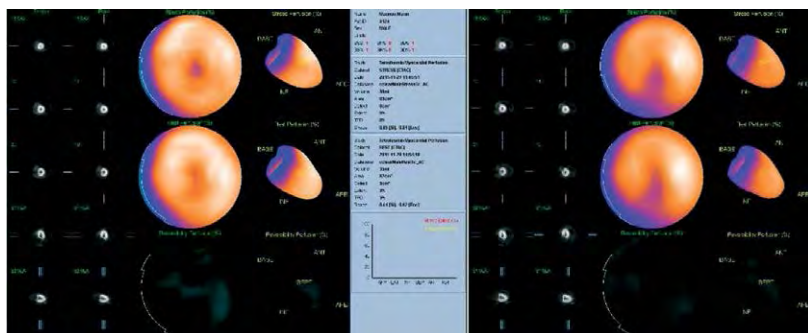


Figure 1. Usual subdiaphragmatic attenuation artifact in inferior wall on right polar maps (without attenuation correction, NAC), absent on left polar maps (with attenuation correction, AC)

correction artifacts. Body truncation during the creation of the attenuation maps, misregistration (Figure 2), patient's motion during acquisition and especially between SPECT and CT should be avoided (10).

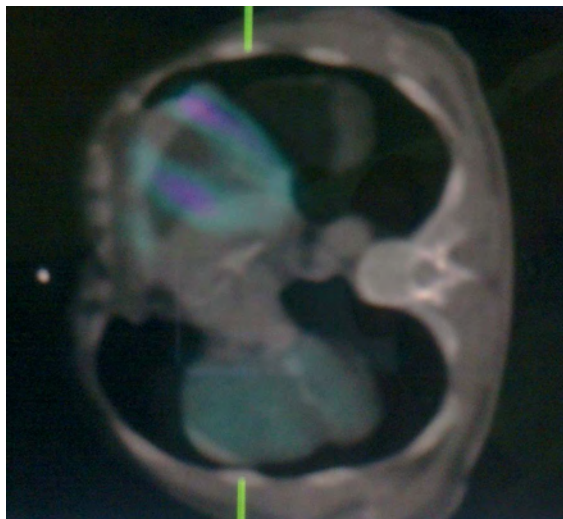


Figure 2. Misregistration, which will create false positive defect

We examined a small group of patients (30) on Siemens Symbia 2T SPECT-CT by stress/rest MPI with ^{99m}Tc tetrofosmin. All patients had known coronary anatomy (by contrast angiography within one month). Quality control on the procedure and on the images fusion was done, in parallel with side by side comparison of AC and NAC images. All low-dose CT scans were verified for unexpected additional findings. Differences in interpretation of AC and NAC MPI were found in 53% of patients. The whole rate of detection of both significant and borderline stenoses increased from 76% by NAC MPI to 94% by AC MPI. Improved sensitivity for the territories of left anterior descendens (LAD) and right circumflex (rCx) arteries was obtained (Figures 3, 4). The increased specificity of RCA territory by 11% was close to other investigators' data (11). AC MPI gave more details in the determination of the defects' reversibility, in viability detection (Figures 5-8) and in the localization of abnormalities (Figures 9, 10).

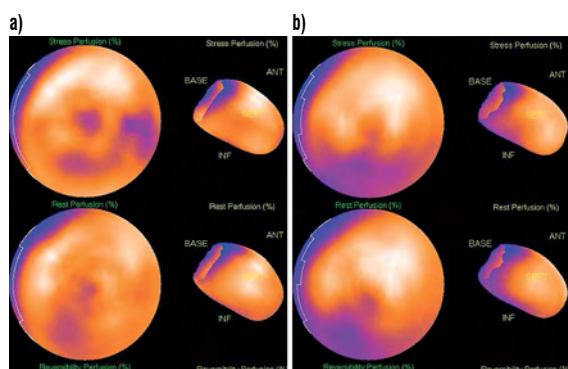


Figure 3a AC and 3b. NAC polar maps. Improved sensitivity for rCx territory on AC polar maps with reversible perfusion defect. On NAC polar maps – only inferior hypoperfusion

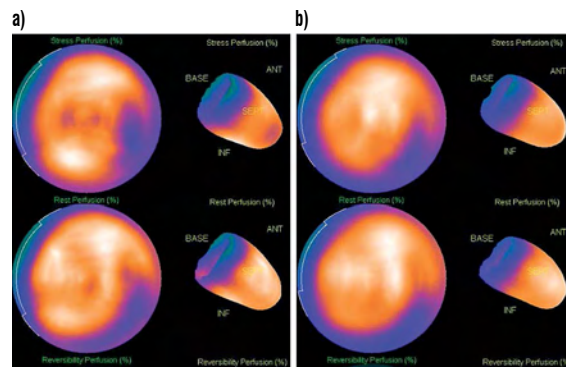


Figure 4a AC and 4b. NAC. Besides the postero-lateral partially reversible defect, more evident hypoperfusion on AC polar maps in the septo-apical region, due to a borderline LAD stenosis

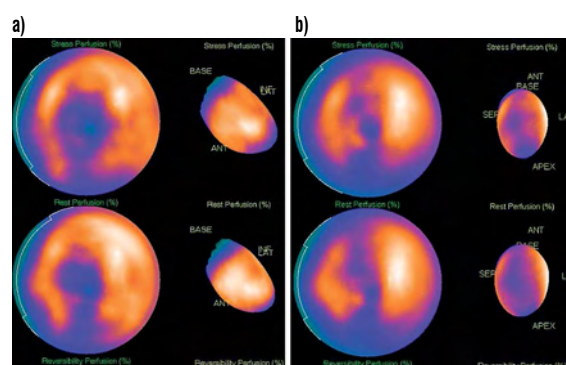


Figure 5a AC and 5b. NAC. Viable myocardium in the postero-septal and infero-lateral areas on AC polar maps, absent on NAC polar maps

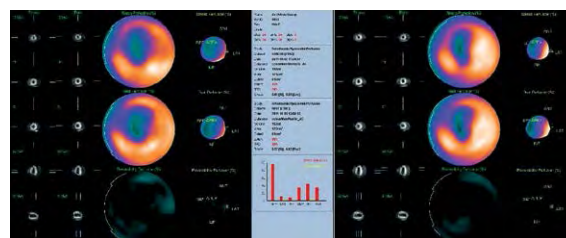


Figure 6. AC and NAC. Fixed anterior defect and reversible antero-lateral defect on AC polar maps (on the left). Fixed anterior defect on NAC polar maps (on the right)

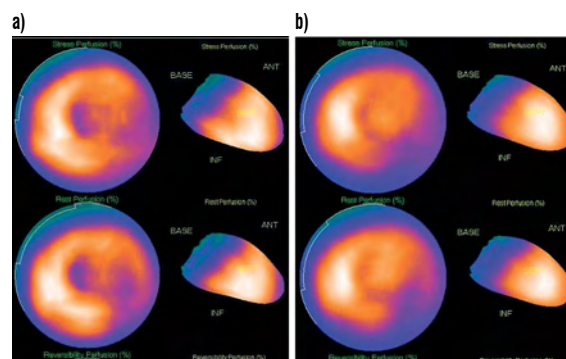


Figure 7a AC and 7b. NAC. More prominent viability in the lateral wall on AC polar maps

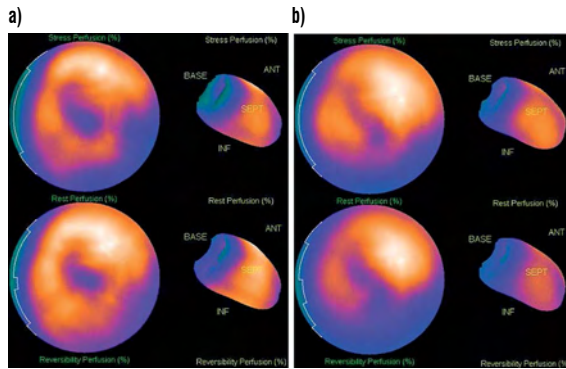


Figure 8a AC and 8b. NAC. More prominent viability in the inferior wall on AC polar maps




Figure 9. AC and NAC slices. Hypoperfusion of the entire anterior wall on NAC slices (bottom rows), versus supra-apical region on AC (top rows)

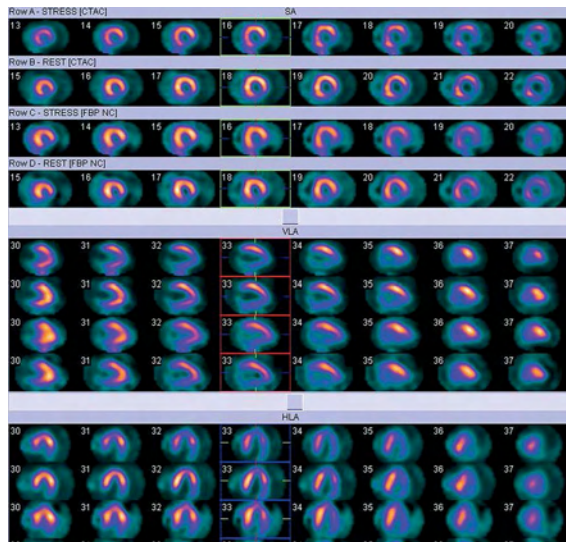


Figure 10. AC and NAC slices. More perfusion abnormalities with multiple distribution on AC slices

The overall current experience confirms the final benefits of attenuation correction for myocardial perfusion scintigraphy: improved diagnostic accuracy and decision making, increased normalcy rate in patients with low probability of coronary artery disease. Additional benefit could be the use of stress-only imaging for patients with low pretest likelihood of CAD, or rest-only imaging in patients with acute chest pain, which are very important for the reduction of exposure. The AC for SPECT MPI enables also improved risk stratification. The prognostically relevant summed stress score (SSS) cutoff shifts toward lower values (12). The review of low-dose CT scan adds important unexpected findings of concomitant extracardiac pathology (e.g. pleural and pericardial effusions, mediastinal masses and pulmonary lesions) in over 10% of examinations (13) (Figure 11).

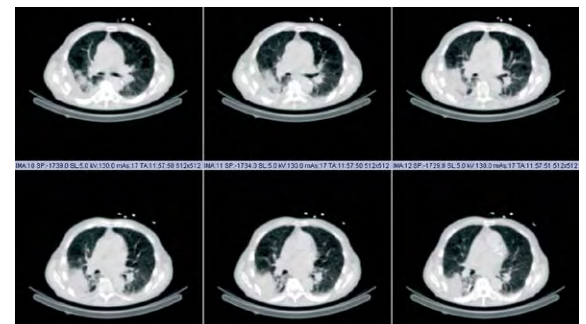


Figure 11. Unexpected pleural effusion and pulmonary mass on low-dose CT

Two other applications of the SPECT-CT for MPI are: (a) the determination of calcium score and (b) the fusion of SPECT-MPI with computed tomographic angiography (CTA).

- (a) The Agatston score (weighted value assigned to the highest density of calcification in a given coronary artery, measured in Hounsfield units) is then multiplied by the area (in pixels) of the coronary calcification. The calcium score of every calcification in each coronary artery for all of the tomographic slices is then summed up to give the total coronary artery calcium score (CAC score). Individuals with Agatston scores above 400 have an increased occurrence of coronary artery procedures and events within 2 to 5 years. Yet, only 20% of coronary plaques are calcified. Besides, even among those patients with CAC scores 1 000, 85% of asymptomatic and nearly 68% of symptomatic patients had a normal MPS study (14).
- (b) Three-dimensional (3D) SPECT/CT image fusion may provide an integrating information, combining SPECT-MPI and 64-slice CTA which are both well established techniques for the noninvasive evaluation of CAD. The fused SPECT/CT images add information on pathophysiologic severity of coronary stenoses (15). They assign very precisely the perfusion abnormalities to a particular vascular territory.

Conflict of interest

We declare no conflicts of interest.

REFERENCES

- 1 Miles J, Cullom SJ, Case JA. An introduction to attenuation correction. *J Nucl Cardiol.* 1999;6:449-57.
- 2 Hendel R. Attenuation correction: eternal dilemma or real improvement. *Q J Nucl Med Mol Imaging.* 2003;49:30-41.

- 3 Tragarth E, Sjostrand K, Jakobsson D, Edenbrandt L. Small average differences in attenuation corrected images between man and women in myocardial perfusion scintigraphy: a novel normal stress database. *BMC Medical Imaging*. 2011;11:18.
- 4 Matsunary I, Boning G, Ziegler SI, et al. Attenuation corrected rest thallium -201/ stress technetium-99m sestamibi myocardial SPECT in normals. *J Nucl Cardiol*. 1998;5:48-55.
- 5 Ficarò EP, Fessler JA, Shreve PD, Kritzman JN, Rose PA, Corbett JR. Simultaneous transmission/emission myocardial perfusion tomography. Diagnostic accuracy of attenuation-corrected ^{99m}Tc sestamibi single photon emission computed tomography. *Circulation*. 1996;93:463-73.
- 6 Links JM, Becker LC, Rigo P, et al. Combined corrections for attenuation, depth dependant blur and motion in cardiac SPECT: a multicenter trial. *J Nucl Cardiol*. 2000;7:414-25.
- 7 Bateman TM, Heller GV, Johnson LL, et al. Does attenuation correction add value to non-attenuation corrected ECG-gated technetium-99m sestamibi SPECT. *J Nucl Cardiol*. 2003;10:S91.
- 8 Gallowitsch HJ, Unterweger O, Mikosch P, et al. Attenuation correction improves the detection of viable myocardium by Thallium-201 cardiac tomography in patients with previous myocardial infarction and left ventricular dysfunction. *Eur J Nucl Med*. 1999;26:459-66.
- 9 Kluge R, Sattler B, Seese A, Knapp WH. Attenuation correction by simultaneous emission-transmission myocardial single photon emission tomography using a technetium-99m labelled radiotracers: impact on diagnostic accuracy. *Eur J Nucl Med*. 1997;24:1107-14.
- 10 American Society of Nuclear Cardiology. Updated imaging guidelines for nuclear cardiology procedures. Part 1. *J Nucl Cardiol*. 2001;8:G5-G58.
- 11 Vidal R, Buvat I, Darcourt J, et al. Impact of attenuation by simultaneous emission/transmission tomography on visual assessment of ²⁰¹Tl myocardial perfusion images. *J Nucl Med*. 1999;40:1301-9.
- 12 Pazhenkottil A, Nikoulou R, Ghadri J-R, et al. Impact of cardiac hybrid single-photon emission computed tomography/computed tomography imaging on choice of treatment strategy in coronary artery disease. *J Nucl Med*. 2011;52 Supplement 1:1110.
- 13 Goetze S, Pannu H, Wahl RL. Clinically Significant Abnormal Findings on the "Nondiagnostic" CT Portion of Low-Amperage-CT Attenuation-Corrected Myocardial Perfusion SPECT/CT Studies. *J Nucl Med*. 2006;47:1312-8.
- 14 Berman DS, Wong ND, Gransar H, et al. Relationship between stress-induced myocardial ischemia and atherosclerosis measured by coronary calcium tomography. *J Am Coll Cardiol*. 2004;44:923-30.
- 15 Gaemperli O, Schepis T, Valenta I, et al. Cardiac image fusion from stand-alone SPECT and CT: Clinical experience. *J Nucl Med*. 2007;48:696-703.